

RESEARCH OUTPUTS / RÉSULTATS DE RECHERCHE

Chondroid metaplasia of paraspinal connective tissue in the degenerative spine

Stevens, Sjoerd; Agten, Anouk; Wisanto, Erika; Monaco, Melissa Lo; Verbrugghe, Jonas; Timmermans, Annick; Lambrichts, Ivo; Vandenabeele, Frank

Published in:
Anatomy and Cell Biology

DOI:
[10.5115/acb.2019.52.2.204](https://doi.org/10.5115/acb.2019.52.2.204)

Publication date:
2019

Document Version
Publisher's PDF, also known as Version of record

[Link to publication](#)

Citation for pulished version (HARVARD):

Stevens, S, Agten, A, Wisanto, E, Monaco, ML, Verbrugghe, J, Timmermans, A, Lambrichts, I & Vandenabeele, F 2019, 'Chondroid metaplasia of paraspinal connective tissue in the degenerative spine', *Anatomy and Cell Biology*, vol. 52, no. 2, pp. 204-207. <https://doi.org/10.5115/acb.2019.52.2.204>

General rights

Copyright and moral rights for the publications made accessible in the public portal are retained by the authors and/or other copyright owners and it is a condition of accessing publications that users recognise and abide by the legal requirements associated with these rights.

- Users may download and print one copy of any publication from the public portal for the purpose of private study or research.
- You may not further distribute the material or use it for any profit-making activity or commercial gain
- You may freely distribute the URL identifying the publication in the public portal ?

Take down policy

If you believe that this document breaches copyright please contact us providing details, and we will remove access to the work immediately and investigate your claim.



Chondroid metaplasia of paraspinal connective tissue in the degenerative spine

Sjoerd Stevens¹, Anouk Agten¹, Erika Wisanto², Melissa Lo Monaco^{3,4}, Jonas Verbrugghe¹, Annick Timmermans¹, Ivo Lambrichts⁴, Frank Vandenabeele^{1,4}

¹Hasselt University, Rehabilitation Research Center, BIOMED Biomedical Research Institute, Faculty of Medicine and Life Sciences, Diepenbeek, ²Department of Pathology, Jessa Hospital, Hasselt, ³Department of Veterinary Medicine, Integrated Veterinary Research Unit-Namur Research Institute for Life Science (IVRU-NARILIS), Faculty of Sciences, University of Namur, Namur, ⁴Department of Morphology, Hasselt University, Faculty of Medicine and Life Sciences, Diepenbeek, Belgium

Abstract: A 51-year-old male was routinely biopsied during a paraspinal muscle study. The biopsy sample was taken from the right erector spinae muscle at the fourth lumbar vertebra. The patient had no history of (diagnosed) major back trauma. The obtained sample was histologically analyzed (hematoxylin and eosin, safranin O), and complementary magnetic resonance imaging was performed. The biopsied sample contained chondroid tissue. Based on its location, the biopsy sample was appointed as chondroid metaplasia. Although chondroid metaplasia is not uncommon in humans, this is the first report of chondroid metaplasia within the paraspinal connective tissue. We propose a novel mechanism to explain the paraspinal chondrogenic changes, related to spinal degeneration.

Key words: Chondroid metaplasia, Paraspinal, Lumbar spine, Degeneration, Muscle biopsy

Received October 16, 2018; Revised December 4, 2018; Accepted December 21, 2018

Introduction

The paraspinal structures within the lumbar spine consist of different muscles, nerves, blood vessels, connective and adipose tissues. The extensor department of the lumbar spine can be subdivided in the three main muscles, i.e., m. Multifidus, m. Longissimus, and m. Iliocostalis [1]. These muscles are surrounded by several fascial and aponeurotic layers that separate them from the posterior abdominal wall musculature. Together these fascial and aponeurotic structures constitute the thoracolumbar fascia [2]. Fascial structures

have the common property that they consist of irregular arranged collagen fibres, in contrast to aponeurotic layers or tendons, in which the collagen fibres are regular arranged [3]. Paraspinal muscles are held together by fibrous connective tissue arranged in different layers. These layers are named the endomysium, perimysium and epimysium, that can all be classified as muscle-specific fascia. All fascial tissue is composed out of a variety of different cells, that are situated within the extracellular matrix (ECM) [4]. The ECM and its progenitor cells most likely play a role in the degeneration of paraspinal muscles and their surrounding connective tissues. The primary cells identified to induce soft tissue degeneration are the mesenchymal progenitor cells, also called fibro-adipogenic cells. These cells have been shown to induce fibrosis and fat infiltration within skeletal muscle tissue [5]. Fibro-adipogenic cells are suggested to contribute to the formation of extraskeletal cartilage and bone [6]. When cartilage tissue is formed in a foreign place outside the skeleton, it is diagnosed as chondroid metaplasia. Chondroid metaplasia is a benign condition, found in connective tissues in response

Corresponding author:

Sjoerd Stevens
Hasselt University, Rehabilitation Research Center, BIOMED Biomedical Research Institute, Faculty of Medicine and Life Sciences, Agoralaan Building A, 3590 Diepenbeek, Belgium
Tel: +32-011269239, Fax: +32-011269329, E-mail: sjoerd.stevens@uhasselt.be

Copyright © 2019. Anatomy & Cell Biology

This is an Open Access article distributed under the terms of the Creative Commons Attribution Non-Commercial License (<http://creativecommons.org/licenses/by-nc/4.0/>) which permits unrestricted non-commercial use, distribution, and reproduction in any medium, provided the original work is properly cited.

to chronic mechanical stress [7], but can also be found in in more malignant conditions, such as breast cancer [8]. To our knowledge, chondroid metaplasia has not yet been described within paraspinal connective tissue.

Case Report

The case identified in this paper pertains to a healthy participant in a study investigating structural muscle characteristics between patients with non-specific chronic low back pain and healthy controls. This study was approved by the local medical ethics committee (15.142/REVA15.14) and complies with the Declaration of Helsinki. Informed consent was given by the patient.

We report a case of chondroid metaplasia within the paraspinal tissue of a 51-year-old male, during a routine paraspinal muscle biopsy procedure [9]. The patient presented completely asymptomatic, reported no history of low back pain, and could not remember any kind of trauma related to his back. The biopsy specimen was histologically analysed, and the patient was referred to the department of radiology (Jessa Hospital, Hasselt, Belgium) for medical imaging of the spinal column.

The biopsy specimen was routinely processed and histochemically stained with hematoxylin and eosin and safranin O. The histological observations revealed the presence of a chondroid tissue. Fig. 1A and B displays the chondrocytes within their lacunae. There were no signs of increased cellularity. Due to the location and the histological aspect of the lesion, a chondrosarcoma can be excluded. Based on its histology, the sample could be misinterpreted as tissue derived from the discus intervertebralis, however this can be excluded based on biopsy site (Fig. 2).

The sample was taken at the right side of the body, at the spinal level of the fourth lumbar vertebra. The distance

between the spinous process and puncture site was 40 mm, the biopsy angle was 35°, and the normal biopsy depth was 22 mm. During this biopsy the needle was not able to reach its full depth because of the resistance when penetrating the chondroid metaplasia.

Magnetic resonance imaging (MRI) showed no deviant findings within the paraspinal musculature. At the level L4–L5 there was slight bulging of the discus superimposed with a small medial hernia, but no impression of the anterior dura. Level L5–S1 showed pronounced degenerative disc disease with pseudo bulging caused by a degree one anterolisthesis (Fig. 3). As a result of anterolisthesis and disc degeneration, caused by a bilateral isthmolysis there was bilateral foraminal stenosis. Both left and right multisegmental degenerative arthritis of the facet joints was present. Because MRI imaging could not provide a solid answer to the origin of the lesion, an

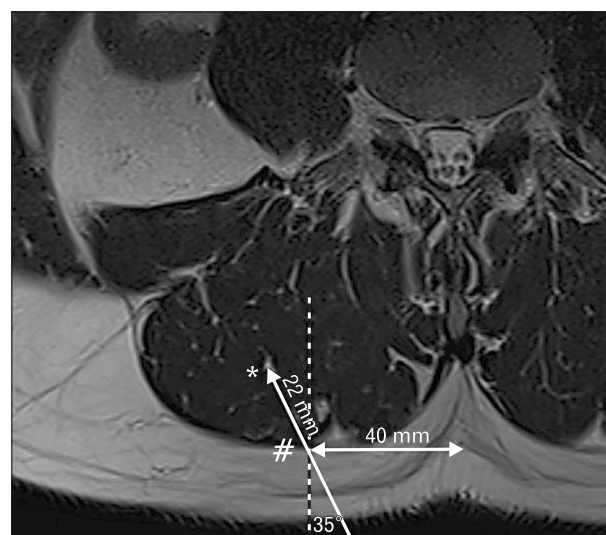

Fig. 2. Biopsy of the right paraspinal muscle. Distance between spinous process and biopsy site, 40 mm; biopsy angle, 35°; normal biopsy depth from fascia (#) into muscle (*), 22 mm.

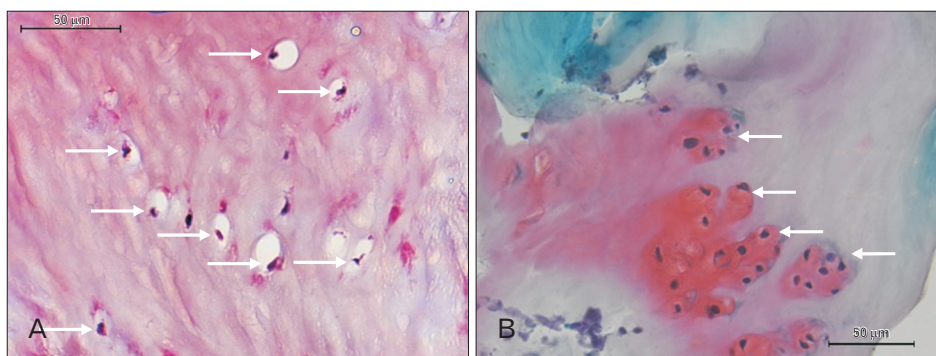


Fig. 1. Hematoxylin and eosin staining ($\times 40$) showing the chondrocytes (black) within their lacunae indicated using white arrows. (B) Safranin O ($\times 40$) showing cartilage (red/orange) and connective tissue (green), nuclei (black); groups of chondrocytes within their lacunae are indicated using white arrows.

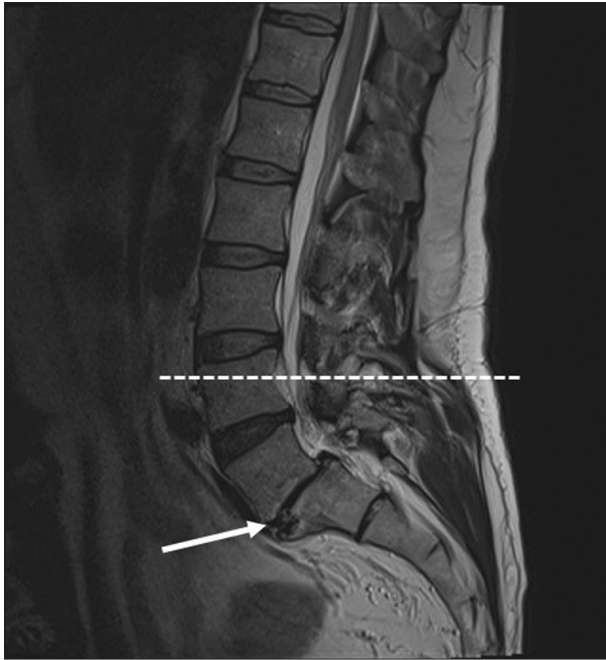


Fig. 3. Sagittal view of T2-weighted magnetic resonance imaging of the lumbar spine indicating disc bulging at L4–L5, pronounced degenerative disc disease at L5–S1 with pseudo-bulging caused by degree one anterolisthesis (white arrow). Biopsy level is indicated (dotted line).

ultrasonography was performed which showed a small insertional calcification on top of the iliac crest. Medical imaging could not provide us with an explanation related to our microscopic findings, but only showed severe spinal degeneration.

Discussion

We describe a case of chondroid metaplasia within paraspinal connective tissue. Based on the biopsy procedure we could indicate the location of the lesion, however we could not identify its exact origin (e.g., muscles, intramuscular septum, or thoracolumbar fascia). The sample did not contain muscle tissue, which makes it more likely that we biopsied the thoracolumbar fasciae or intermuscular septum. To date there have been no reports on benign chondroid changes within paraspinal connective tissues in patients with degenerative spinal conditions. However, there have been reports on paraspinal muscle degeneration in patients with isthmic spondylolisthesis [10] and other degenerative spinal pathologies [11]. The mesenchymal derived progenitor cell might play an important role in chondroid metaplasia within the paraspinal

fascia and muscle. Under normal circumstances these cells give rise to fibroblasts that produce the ECM [4, 5]. Mesenchymal derived cells have already shown their osteogenic and chondrogenic potential [5, 12]. It is possible that osteogenic cytokines or dysregulation of bone morphometric protein signalling within an inflammatory context could play a role in the process of transforming mesenchymal derived cells into chondroid metaplasia [6]. The role of local inflammation has already been identified through muscular changes in persons with spinal pathology, such as fibrosis and fatty degeneration [13, 14]. We suggest the existence of a connection between degeneration of the spine and changes within the paraspinal connective tissues. This proposition is based on the interaction between mesenchymal derived progenitor cells and local inflammation seen in spinal pathologies.

We presented the first case of chondroid metaplasia within paraspinal connective tissue, combined with severe spinal degeneration. Our microscopic findings could not be explained through medical imaging. Although in this case the chondroid metaplasia did not lead to clinical symptoms, the presence of chondroid metaplasia within the lumbar spine might be linked to spinal degeneration, trauma or strong stress and should not be neglected. To date, the clinical value of this chondroid metaplasia within the degenerative spine is not clear. Large-scale surveys using cadavers can be further needed, since chondroid metaplasia in the lower back can be discovered by chance in asymptomatic subjects.

Acknowledgements

We would like to thank dr. Geert Souverijns from the department of radiology at the Jessa Hospital Hasselt (Belgium), for taking and interpreting the medical images.

References

1. Bogduk N. A reappraisal of the anatomy of the human lumbar erector spinae. *J Anat* 1980;131:525-40.
2. Willard FH, Vleeming A, Schuenke MD, Danneels L, Schleip R. The thoracolumbar fascia: anatomy, function and clinical considerations. *J Anat* 2012;221:507-36.
3. Clemente CD. *Gray's anatomy of the human body*. Philadelphia, PA: Lea & Febiger; 1985.
4. Zullo A, Mancini FP, Schleip R, Wearing S, Yahia L, Klingler W. The interplay between fascia, skeletal muscle, nerves, adipose tissue, inflammation and mechanical stress in musculo-fascial regeneration. *J Gerontol Geriatr* 2017;65:271-83.
5. Uezumi A, Ikemoto-Uezumi M, Tsuchida K. Roles of nonmyo-

- genic mesenchymal progenitors in pathogenesis and regeneration of skeletal muscle. *Front Physiol* 2014;5:68.
6. Wosczyzna MN, Biswas AA, Cogswell CA, Goldhamer DJ. Multipotent progenitors resident in the skeletal muscle interstitium exhibit robust BMP-dependent osteogenic activity and mediate heterotopic ossification. *J Bone Miner Res* 2012;27:1004-17.
 7. Shon W, Folpe AL. Myxochondroid metaplasia of the plantar foot: a distinctive pseudoneoplastic lesion resembling nuchal fibrocartilaginous pseudotumor and the equine digital cushion. *Mod Pathol* 2013;26:1561-7.
 8. Myint ZW, Raparla S, Kamugisha LK. Metaplastic breast cancer with chondroid differentiation. *J Community Hosp Intern Med Perspect* 2015;5:28935.
 9. Agten A, Verbrugghe J, Stevens S, Boomgaert L, B OE, Timmermans A, Vandenabeele F. Feasibility, accuracy and safety of a percutaneous fine-needle biopsy technique to obtain qualitative muscle samples of the lumbar multifidus and erector spinae muscle in persons with low back pain. *J Anat* 2018;233:542-51.
 10. Thakar S, Sivaraju L, Aryan S, Mohan D, Sai Kiran NA, Hegde AS. Lumbar paraspinal muscle morphometry and its correlations with demographic and radiological factors in adult isthmic spondylolisthesis: a retrospective review of 120 surgically managed cases. *J Neurosurg Spine* 2016;24:679-85.
 11. Park MS, Moon SH, Kim TH, Oh J, Lee SJ, Chang HG, Shin JH. Paraspinal muscles of patients with lumbar diseases. *J Neurol Surg A Cent Eur Neurosurg* 2018;79:323-9.
 12. Lees-Shepard JB, Yamamoto M, Biswas AA, Stoessel SJ, Nicholas SE, Cogswell CA, Devarakonda PM, Schneider MJ Jr, Cummins SM, Legendre NP, Yamamoto S, Kaartinen V, Hunter JW, Goldhamer DJ. Activin-dependent signaling in fibro/adipogenic progenitors causes fibrodysplasia ossificans progressiva. *Nat Commun* 2018;9:471.
 13. James G, Sluka KA, Blomster L, Hall L, Schmid AB, Shu CC, Little CB, Melrose J, Hodges PW. Macrophage polarization contributes to local inflammation and structural change in the multifidus muscle after intervertebral disc injury. *Eur Spine J* 2018; 27:1744-56.
 14. Hodges P, James G, Blomster L, Hall L, Schmid A, Shu C, et al. Multifidus muscle undergoes structural remodeling of muscle, adipose and connective tissue, but not atrophy after injury: molecular and morphological evidence. *Physiotherapy* 2015; 101(Suppl 1):e581.