

## RESEARCH OUTPUTS / RÉSULTATS DE RECHERCHE

### The human testes

Hussain, Aatif; Gilloteaux, Jacques

*Published in:*  
Translational Research in Anatomy

*DOI:*  
[10.1016/j.tria.2020.100073](https://doi.org/10.1016/j.tria.2020.100073)

*Publication date:*  
2020

*Document Version*  
Publisher's PDF, also known as Version of record

#### [Link to publication](#)

*Citation for published version (HARVARD):*  
Hussain, A & Gilloteaux, J 2020, 'The human testes: Estrogen and ageing outlooks', *Translational Research in Anatomy*, vol. 20, 100073. <https://doi.org/10.1016/j.tria.2020.100073>


#### General rights

Copyright and moral rights for the publications made accessible in the public portal are retained by the authors and/or other copyright owners and it is a condition of accessing publications that users recognise and abide by the legal requirements associated with these rights.

- Users may download and print one copy of any publication from the public portal for the purpose of private study or research.
- You may not further distribute the material or use it for any profit-making activity or commercial gain
- You may freely distribute the URL identifying the publication in the public portal ?

#### Take down policy

If you believe that this document breaches copyright please contact us providing details, and we will remove access to the work immediately and investigate your claim.



## The human testes: Estrogen and ageing outlooks

Aatif Hussain<sup>a</sup>, Jacques Gilloteaux<sup>a,b,\*</sup>

<sup>a</sup> Department of Anatomical Sciences, St George's University School of Medicine, KBT Global Scholar's Program, Newcastle Upon Tyne, NE1 8ST, United Kingdom

<sup>b</sup> Department of Medicine, NARILIS - Unit of Research in Molecular Physiology (URPHYM), Université de Namur, 5000, Namur, Belgium

### ARTICLE INFO

#### Keywords:

Testis  
Receptors  
Estrogen  
Testosterone  
Leydig cells  
Sertoli cells  
Human  
Aging  
Gonadotrophins  
Crystalloids  
Pathology  
Xenobiotic  
Public health  
Contraception

### ABSTRACT

This survey highlights some of the fine structures and functions associated with estrogen in the human testes, ageing and contraception. Clarifications obtained with knockout mice models as well as some clinical investigations showed that estrogen receptors significantly influenced the overall maintenance of the testis functions through aromatase activity, intervening in the testosterone production by the Leydig cells and, indirectly with the Sertoli cells. Other autocrine, paracrine and endocrine fading activities of the seminiferous tubule's interstitium, including vascular supply, curtail the maturation of the male gametes while maintaining the blood-testis barrier in ageing. Do Reinke, Charcot-Böttcher and Lubarsch crystalloids, biopsy markers of specific testis cells, resulted of normal or altered functions and/or accumulated deposits out of ageing? The hypothalamo-pituitary-testis axis and feed-back homeostasis (with pineal influence?) regulating the reproductive tissues and phenotype characteristics, can be progressively changed according to individual health history, encompassing life time accumulated environmental toxicants, pharmaceuticals, and age-reduced cardiovascular fitness. The monitoring of all those long-term effects is needed to be better understood to provide future human public health in the care for the old adult, aging population.

'Causa latet, vis est notissima' [The cause is hidden, the result is very evident], Ovidius, *Metamorphoses*, IV. 287.

### 1. Introduction

Biomedical science's courses comprise studies on the reproductive systems in which gonads in all animals, including humans, are included. The male testes (or testicles) as in "two together", considering the slang uses in the Ancient Greek *παράσταται* (i.e. *parastátai*, "colleagues"), are homologous to the female ovaries. There, the developed and mature structures and functions classic views are that the developed and matured structure and functions of the testes are regulated by the episodic hypothalamus gonadotrophin (GnRH) secretions whose stimuli act via the hypothalamo-pituitary portal vessels to induce a pulsatile expression of both secretions of some of the basophil and eosinophil cells of the anterior pituitary gland: the luteinizing hormone (LH) and/or the follicle-stimulating hormone (FSH). Thus, on one hand, classic view notes that LH influences the interstitial cells of Leydig's LH receptors (LHR) to produce the gonadal testosterone (T) to influence spermiogenesis of the spermatogenesis and making androgens, including dihydrotestosterone (DHT). Levels of T free serum and transported by a

circulation carrier, with that of DHT, also contribute in characterizing the 'male' phenotype, by influencing other accessory male reproductive organs and tissues. On the other hand, FSH has receptors on Sertoli cells of the seminiferous tubules and upstream ducts exiting the testes modulating spermatocytogenesis of the spermatogenesis i.e. taking the haploid spermatogonia to spermatocytes and producing estrogens and having receptors for it. These sex steroid secretions of the testes feed back to that hypothalamo-pituitary axis and are also autocrine to their tissues of origin [i.e. 1-3]. (see [Table 1](#))

Characteristically associated with the female gender or sex as 'female' sex steroid hormone, discovered to cycle the guinea pig, a century ago [4,5], estrogen and estrogen receptors have also been detected in different cells of male's organs about 20 years later [6].

Ageing changes can modify the male organs and steroid influences as hormonal activities linked with the typical testes functions thus, **estrogen** changes would reveal a lesser considered aspect of the human male reproductive system resulting in or accompanying other disorders, including prostatic cancer. This apparently minor estrogen functions in the male reproductive system along with some of these aforementioned topics, have not and are not yet even alluded in textbooks of microscopic anatomy and should get adjusted with pathology and physiology.

\* Corresponding author. Department of Anatomical Sciences, Drill Hall 0013 at UNN- School of Life and Health Sciences, St George's University School of Medicine, KBT Global Scholar's Program, Newcastle upon Tyne, NE1 8ST, United Kingdom.

E-mail address: [jgilloteaux@sgu.edu](mailto:jgilloteaux@sgu.edu) (J. Gilloteaux).

<https://doi.org/10.1016/j.tria.2020.100073>

Received 14 January 2020; Received in revised form 24 March 2020; Accepted 24 March 2020

Available online 24 April 2020

2214-854X/ © 2020 The Authors. Published by Elsevier GmbH. This is an open access article under the CC BY-NC-ND license (<http://creativecommons.org/licenses/by-nc-nd/4.0/>).

**Table 1**  
Testis and main E2 Receptors in Human Seminiferous Tubule Cells.

Stroma Myoid cells	LCs	SCs	Spgonia	Spyctes	Spids	Spzoa
ER-As	ER-Bs	ER-As	ER-Bs	ER-Bs	ER-As	ER-Bs

Abbreviations: ER-As = E2 alpha receptors; ER-Bs = E2 beta receptors; LCs = Leydig cells; Scs = Sertoli cells; Spgonia = Spermatogonia; Spcytes = Spermatoocytes; Spids = Spermatids; Spzoa = Spermatozoa; Stroma: mainly myoid cells.

After more than 40 years in biomedical publications, it is time to reveal these basic hormonal, homeostatic activities, especially since general practitioners have to be trained to likely later provide care to an increased ageing population and stimulate further translational investigations [7]. Perhaps the neglected actions of the pineal, in view of seasonal or cyclic influences mainly relegated or considered for rodents [8] and those of prolactin, made by the acidophil cells of the pituitary gland as suggested by some tumors [7,9–13] could render later on the topic even more complex, but worth considering, in view of modern living behaviors and the complex medical problems of the individual. This can include portrayals brought by unprepared media when transgender and gender changes are brought into public sensationalism.

In this brief review, we have also attempted to highlight the known functions of estrogen in mature males and considerations about the antagonistic effects of estrogen-like or xenosteroid disruptors favoring some of the structural and dysfunctional atrophy bearing functional similarities of the aged human conditions (decreased sperm counts, cryptorchidism, hypospadias and testicular cancer) [14–17].

## 2. Materials

This survey has been created out of from literature searches throughout public access systems, including the public accessed United States Library of Medicine internet site (<https://www.ncbi.nlm.nih.gov/pubmed>) as well as Google search access. Illustrations were obtained out of old microscopic preparations available to medical and biomedical students, at the University of Namur, Namur, Belgium, made by and for the Laboratory of Cells and Tissues between 1965 and 1980 out of necropsies from human body donations. Those histology sections were prepared out of at least one human adult (> 40 year old male) and another sample from specimens from an elderly (> 80 years of age), after body perfusion embalming, tissues were further fixed in formalin and processed in paraffin sections, stained with either hematoxylin-eosin or trichrome stain and accessible through [www.histology.be](http://www.histology.be) internet site.

## 3. Estrogen

### 3.1. Terminology

Named originally ‘oestrin’ and isolated as ‘an ovarian hormone’ by Nobelists Allen and Doisy [18] and Butenandt [19]. The steroid is involved in cyclical changes associated with procreation, or oestrus [20,21], a topic reviewed in Medvei [22]. The American English ‘estrogen’ for the English ‘oestrogen’ is used throughout this survey. It is derived from ancient Greek ‘οἶστρος’ (or oistros, meaning ‘oestrus’ as ‘inspiration’ meaning figuratively ‘sexual passion or desire’) and a suffix ‘γένος’ (or genos as ‘producer of’) i.e. generating the periodic state of sexual activity of females of most mammals [23]. The term ‘estrogen’ as used in the previous paragraph and in the following text is meant ‘female sex steroids’ and as a ‘general’ term used to encompass, in male tissues, the following three steroids and their metabolites: estrone (E1) has one, estradiol (E2) has two, estriol (E3) has three hydroxyl groups. However, 17β-estradiol (estradiol or E2) is the most prevalent in activity of E1, E2 and E3 in human and mammals; another type of

estrogen, called estetrol (E4), produced during female pregnancy, was evidently not included [23–25]. Thus, E2 abbreviation used is for all sex steroid estrogens throughout the text, including those circulating in lesser amount or/and active metabolites.

### 3.2. E2 functional aspects and gender differences

E2 is commonly known as a hormone secreted by the ovaries throughout the reproductive span of reproductive activity in the female. Ovary estrogen is responsible for various mechanisms ranging from forming the female phenotype, promoting the cyclical growth of follicles, and preparing for pregnancy several organs to reducing inflammatory effects in females [26], and even the level of pain perception [27]. The ovaries are the major source of circulating estrogens in females as evidenced by oophorectomy, entirely removing estrogen; this simple amputation has allowed a more clear and early understanding of estrogen functions in cases of endocrine dysfunctions. This is in contrast when compared in males where a diffuse production of estrogen meant that there are intricate estrogen-deficient productions and thus, less understood. It has been documented that estrogen plays a large role in spermatogenesis and in maintaining libido [28]. Estriol [E2] is a most active form of estrogen steroid molecule that has been found to be a clinically significant; however, compared with the female gender, E2 level in men is still above that found in postmenopausal women [29,30] and is able to carry out the endocrine and autocrine effects noted in the human male reproductive system [9,30–37].

### 3.3. E2 production is through consumption of testosterone by CYP19A1 aromatase

Revisiting biochemistry basics, one recalls that cholesterol is the precursor molecule modified by the desmolase CYP11A into pregnenolone, then by a mitochondrial dehydrogenase into progesterone. This latter becomes testosterone (T) through CYP17 hydroxylase activity [3,7,28–37], a member of the cytochrome P450 reductase enzyme superfamily. Finally, another cytochrome P450 reductase enzyme CYP19A1 (aromatase or EC 1.14.14) modifies T into E2 and related steroid metabolites. This key enzyme is required for E2 production; it not only plays a crucial role in testicular maintenance but it consumes T produced by Leydig cells in the interstitium. T has been shown to decrease with age in both humans and rodents [3,8,9,15,30–39] and, thus, the plasma level T and some of its metabolites, with inhibin, can influence back the same hormone’s release by gonadotrophs to see an E2 increased in seminal plasma [39,40].

T actions throughout the male body has anabolic actions and on specific reproductive organs can be episodically stimulated and mostly converted as E2, as mentioned above. A small other source of E2 is androstenedione, originating from the suprarenal zona reticularis. Recent studies showed that human CYP19A1 gene is located in the 21.2 region of the long arm of the chromosome 15 (i.e. 15q21.2 region [41]. In addition to regulatory regions, this gene contains nine exons (exons II–X) and contains 10 promoters, which are used according to the needs and the characteristics of the tissue [42,43]. In comparison, mouse CYP19 gene is localized on chromosome 9 where three promoters specifically control the CYP19A1 gene expression [44]. Human aromatase is mostly found in adipose tissues and only 10–25% in the testes [6,31,45]. In final, the proper action of E2 as steroid depends on two main factors: (i) the T converting enzyme and (ii) its receptors found in various tissues and organs of the human male human including the brain, the adipose and bone tissues, the skin (including the mammary glands), the testes and the penis [3,30–37]. In comparisons, reports suggest that high T concentrations inhibit spermatogonia proliferation in models when spermatogenesis has been damaged by processes such as irradiation [46]. During meiosis, T stimulates the progression of spermatocytes through this process and inhibits apoptosis [47], and as seen later. E2 may there be co-operating with it. The

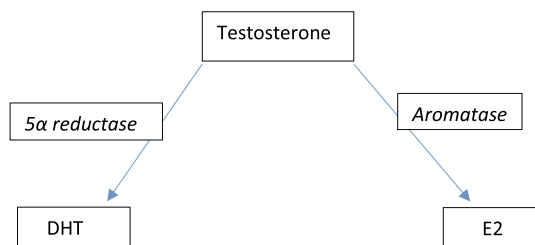
site of action of androgens in spermatogenesis has been extensively studied [48–51].

The diffuse E2 production in males means that there are potential complex endocrine dysfunctions in male's E2-deficient productions compared with females. This diversity of actions due to receptors and multiplicity of target tissues has probably hindered progress in the understanding of clinical deficient cases and patterns of the male human tissues [6,9,38,40]. Even though numerous biomedical studies have used successfully murine models to clarify the many sites of aromatase activities, one may still be careful in validating those data for humans which may still have differences in functionality or regulations [30–40,45–52]. Aromatase, the main enzyme converting androgens to E2, is also found in Leydig cells, Sertoli cells, germ cells and elongated spermatids in the male reproductive system [37,38]. Therefore, if any of these locations housing aromatase were to decrease or disappear, a reduction in E2 production would result. Factors known to increase aromatase activity include age, obesity, insulin, gonadotropins, and alcohol. Aromatase activity is antagonized or decreased by prolactin, anti-Müllerian hormone and the common herbicide glyphosate [15,17] and explained in further paragraphs] and, in elderly, could it be that T is tapped by 5- $\alpha$  reductase (EC 1.3.99.5) into more dihydrotestosterone (DHT) and eventually favor benign prostatic hyperplasia (BPH) and prostate cancer? [39] (Fig. 1).

In female, aromatase activity appears to be enhanced in certain E2-dependent local tissue next to breast tissue, endometrial cancer, endometriosis, and uterine fibroids. At this point, one could likely generalize that E2 (and some of its metabolites) or synthetic E2 (i.e. diethylstilbestrol or DES) are known to entice body receptive cells to enter the cell cycle by stimulating DNA replication and typical or altered transcripts, especially in cases of excessive unbalanced circulating levels, estrogen would favor carcinogenesis [53–61]. E2 was found in human testes Sertoli cells adenocarcinomas [48,51]. During differentiation, germ cells are able to synthesize E2, acting as intracrine or autocrine modulating factors of their own maturation [48–51]. E2 and environmental non-estrogens but with E2-like activities have been shown to be able to stimulate mammalian sperm capacitation, acrosome reaction and fertilizing ability [60]. Many of these E2 effects were mediated by cognate receptors, ligand-activated transcription factors, binding to responsive components of the hormone-responsive genes [37,38,45,53,54,60–65].

### 3.4. Aromatase excess syndrome and stress

A rare syndrome where in boys due to mutations in the CYP19A1 gene can induce gynecomastia and precocious puberty accompanied by a rapid epiphyseal closure that leads to short stature. This condition is inherited as an autosomal dominant fashion but the long-term anti-aromatase treatment into adulthood and further is unknown [66,67]. Excess aromatase activity can be caused by medical procedures involving serious cardiovascular risks surgeries [68,69].



**Fig. 1.** The role of estrogen in the ageing process of the male reproductive system appears to be triggered by the lack of blood flow to testicular cells. While estrogen does not appear to play a role in initiating testicular atrophy, it demonstrates the effect of promoting degeneration that is already in progress.

### 3.5. Aromatase deficiency syndrome

This syndrome is found in youth, caused by a mutation of gene CYP19 and inherited in an autosomal recessive way. Accumulations of androgens during pregnancy may lead to intact males but tallness due to retarded epiphyseal closure. The aging outcome of this defect is unclear at this time [70–72] while some effect could be preventative of osteoporosis and can be worth further exciting clinical investigations [73].

### 3.6. Inhibition of aromatase and environmental toxicology

This inhibition can result in hypoestrogenism and can be caused by pharmacy and natural products, still quasi exclusively studied in women [74–77]. These compounds are aimed to inhibit the production of E2 in postmenopausal women; thus, a current clinical usage of anastrozole, exemestane, and letrozole as they became useful in the management of patients with breast cancer lesions found to be E2 receptor positive. Aromatase inhibitors are also beginning to be prescribed to men on T replacement therapy as a way to keep E2 levels from spiking once doses of T are introduced to their systems. Natural aromatase inhibitors tend to cause fewer serious side effects than tamoxifen and related medications in elderly patients which can cause or favor the heart, venous thromboembolic events (VTE), stroke and frequent osteoporosis in some cases, and has yet to be evaluated more in male patients [e.g. Ref. [69,73]. Other common disruptors of aromatase are widely used in agriculture as herbicide and antifungal and their long term toxicity measured in vitro and evaluated in cohorts of patients could harbor a large number of defects that are still to grow in diagnostic among many farming populations, ignored by industrial agriculture developments, unawareness or neglect of administrative policies in public health [e.g. Ref. [74–88]. Finally, among traffic pollutants, lead can affect fertility and therefore it is crucial that long-term clinical surveys would verify this environmental public topic [78].

## 4. E2 production and the testes

The finding of the E2 source in human testes was originally derived from dog experimentations [89] when rare Sertoli cell's tumors were observed (e.g. Ref. [90,91]) or in some forms of seminiferous tubule anomalies [92], varicocele [93] and cryptorchidism [37,94,95]. These histopathologic structures induced by exogenous E2 were even more pronounced when fetal or neonatal animals were exposed developmentally to high E2 levels though of synthetic diethylstilbestrol (DES) or other natural or man-made environmental estrogens [93]. Those stimuli can produce permanent changes in the structure and function of postnatal human male reproductive organs, similarly as those found in females using rodent model offspring through more than one generation [49,54–62,93]. Most of the DES animal studies have been especially important because they have predicted some of the extensive male abnormalities after DES exposure during pregnancy [62,94,95] caused by the intratesticular sites of aromatization in the developing tissues of human testes [36–38]. Measurement of E2 in peripheral blood and urine [49,52] indicated that E2 is 'very low in humans' and that 'estrogen levels were also found in testis and in semen' [96]. The primary source in immature testes was first hypothesized to be Sertoli cells, confirmed by the Sertoli cell tumors, and later with in vitro studies [90,91,97]. Then, direct evidence that normal Sertoli cells can synthesize E2 under the regulation of FSH and cyclic AMP. However, in adult and aging testes, studies have always consented that the main E2 source was Leydig cells [6,8,12,21,29,32–40,98–100] as proposed by Western and Northern analyses [41,60–62,68,69]. Meanwhile, aromatase was also localized by immunohistochemistry [74] in spermatogonia, elongating spermatids and other associated tissues and organs of the male reproductive system [9,32–40,60,61,70–73,100–103].

#### 4.1. E2 receptors

E2 hormone receptors (ERs) are located intracellularly in a similar distribution as aromatase. In the testes seminiferous tubules, these receptors are localized in the cytoplasm and Golgi of the round spermatids [32–37] while at least two types of ERs have been identified in females, ER-alpha or  $\alpha$  (ER-A) and ER-beta or  $\beta$  (ER-B); the same ones have been found in males [104–107]. The most abundant ER found in males is the ER-B form which is ubiquitous to almost every cell in the interstitium and seminiferous tubules, but the ER-A, located specifically in that interstitium have been found to play a key role in maintaining a differentiated epithelium morphology and to regulate fluid reabsorption in the male reproductive system [32–37,104–109]. ER-A Knock Out (ERA KO) studies conducted in mice have found the tall, ciliated columnar shaped epithelial cells of the efferent ductules with abundant microvilli to undergo metaplasia towards smaller, cuboidal shaped cells with sparse microvilli.

E2 receptor makes possible to influence the differentiation of the efferent ductular epithelium [105]. As KO studies indicated, compromising ERs lead to atrophy and other morphological changes of the cells they reside, thus, a lack and/or any compromised ERs could therefore potentially be linked with testicular atrophy, also correlated with the natural ageing process. E2, as any steroid hormone, diffuses through plasmalemma, acts through nuclear receptors to ultimately regulate gene transcription and expression in a similar distribution as the aforementioned aromatase in the testes [e.g. 32–37, 108–109]. Animal models, such as rabbit, rats and mice (wild and KO) studies with the use of radiolabeled E2, initiated by Mulder and the group of van Beurden-Lamers [105,106,108] have been able to make the human physiology understood about the E2 role in the male reproductive system, along with the understanding of E2 receptor biology. Out of a study conducted in 1996, knocking out (KO) estrogen receptors in male mice, in particular the ER-A, exhibited a pattern of progressive testicular tissue degeneration [111]. This further supported by more recent studies indicating that the ER-A is implied to mediate testicular germ cell differentiation through a mechanism involving Sertoli cells [112,113]. It should be noted that rats ER-A KO showed no significant impairment in spermatogenesis; this is in stark contrast with aromatase KO studies [111]. These findings exemplify the higher function E2 synthesis and presence plays in spermatogenesis and overall testicular health. The ERs are required for the effects of E2 to be observed thus, a destruction of these receptors can come along with the effects of testicular changes through ageing, thus can help further progress toward their involution process. Other studies investigated the opposite end of the spectrum by artificially increasing the production of ERs in mice which lead to Leydig cell hyperplasia, cryptorchidism and undescended testis all resulting in lower testosterone levels [30,63]. These other data could potentially be due to a shunt-like effect where an increased number of receptors for E2 calls for an increased production of E2 thus depleting testosterone levels halting the dissention of the testis, one of the effects of normal testosterone function. With increased amount of E2 receptors linked with Leydig cell hyperplasia, it can logically be extended that a lack of E2 can potentially result in hypoplasia, decreased function and eventual testicular atrophy in the human male reproductive system. Reports on human testis tissues [38,40,100–108,113–122] showed most cells with both ER-A and ER-B receptors but with Leydig cells and spermatogonia with quasi only ER-B. Another large series of other reports are quoted in Ref. [37,38] while another review is mainly dealing with the huge number of murine experiments [100–103]. One should note that these conclusions only hold true if mice are assumed to be adequate models for human males. These animal model studies hold a strong argument for parallel investigation towards human ageing and could potentially further aid in the search for a method to slow or extinguish the natural ageing process of the male reproductive system where a proper balance between T and E2, through aromatase activity, is key for an appropriate functioning during reproductive activity. In

the meantime, a large number of studies have verified those receptor's action in primates, normal human and in pathology [65–72,113–138] as well as medication against male osteoporosis [73].

#### 5. Tunica vaginalis

The tunica vaginalis, serous membrane lining the human testis, developed from the peritoneum [139,140] and, thus, pediatric testes are considered intraperitoneal because the tunica vaginalis, a peritoneum derivative, covers the testes. Studies have shown that, with ageing, this usually liquid lining can adhere to the testis wall and obliterates the mesentery present on the testis. Thus, with ageing, the testes appear behind the tunica vaginalis rather than inside [140]. This loss of lining has been observed in other conditions such as cryptorchidism which has been associated with testicular atrophy [123]. If this lining has been shown to be diminished in the elderly and a pathological loss of it has been linked to testicular atrophy; therefore, it should be reasonable to accept that the tunica vaginalis plays some key anatomical role in maintaining testicular health.

#### 6. Testis interstitial cells of Leydig or interstitial endocrinocytes

##### 6.1. Ageing and hypogonadism?

The interstitial cells of Leydig (LCs), officially-named 'interstitial endocrinocytes' [141], can be detected in the testis stroma, and usually found adjacent to the seminiferous tubules [142–163]. A population of 'fetal'-type mesenchymal cells are destined to become LCs from the 8th to the 20th week of gestation, and produce enough testosterone until birth and at puberty. 'adult'-type LCs differentiate in the post-natal testis. Indeed, they are preceded in the testis by masculinization of a male fetus [7–10,14,34–37,99,156,157]. Leydig cells respond to LH from some of the basophils of the anterior pituitary gland to produce T in males with a decreased quality and production according to aging in rodents [158,159] and humans [157,160], thus sustaining the gender phenotype. LCs markers should express T through aromatase (see above paragraphs) and Reinke crystal location [161,162], but also can be identified through histochemical markers such as calretinin [162–166], more specifically than with inhibin [167,168].

Mature LCs are polyhedral in shape, and have a large prominent ovoid nucleus containing a prominent nucleolus, an eosinophilic cytoplasm with mitochondria, endoplasmic cisterns and numerous lipid-filled vesicles, lipofuscin pigment and peculiar, rod-shaped crystal-like structures (3–20  $\mu$ m in diam.), as named 'crystalloids of Reinke' of no known function [142–151], besides to be eventual marker of LC tumors [160, 161, see paragraph 5.5] and Fig. 2 A-B versus Fig. 3 A-B.

LCs undergo obvious cell changes as the person ages [99–104,156,157,168] and the same studies showed with a murine

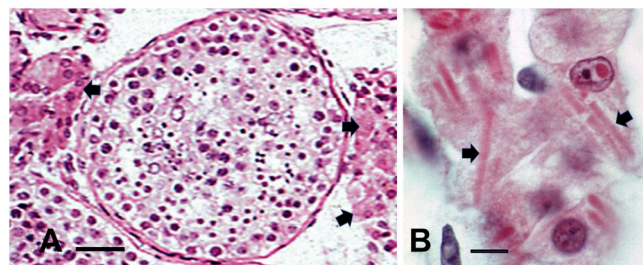
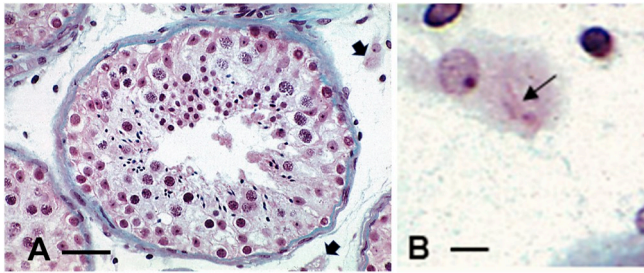


Fig. 2. A-B Light microscopy preparation out of paraffin sections from a mature human testis where the seminiferous tubules sections are busy by lining spermatogonia and other progeny gonocytes and spermatids. In the stroma, many small circulatory vessels are surrounded by large eosinophil aggregates of Leydig cells (arrows). B: enlarged aspects of Leydig cells containing Reinke crystalloids as elongated rod-like shapes (arrows). Scale in A is 20  $\mu$ m; in B it is 5  $\mu$ m.



**Fig. 3.** A-B Light microscopy preparation out of paraffin sections from an elderly human testis where the seminiferous tubule sections display a poor lining and luminal content, a thickened basal membrane, when compared to mature testis (Fig. 2A). The stroma appears poorly populated due to a poor stromal cell population, including Leydig cells. They are rare and scattered (arrows) among the stromal spaces with vacuolated content (lipids) and only small Reinke crystals (arrow). Scale in A is 20  $\mu\text{m}$  and in B is 5  $\mu\text{m}$ .

model of accelerated Leydig cell ageing by knocking out the Nrf2 gene responsible for protection against oxidative stress which led to loss of cytoplasm and eventual atrophy of the cells as in primary hypogonadism [168]. Such deficiency and in excess have been reported by some of the early studies with histology in mammals, among others, the equine type and human [142–151], (see Fig. 2A and B), including electron microscopy [146–152,154,155]. All LCs can produce T in the presence of LH, as first demonstrated in mouse [37,111,152] which level decreases with age as noted in rats [158,159], like those found in human [30–37,147–162]. Age-related defects include altered transport of cholesterol, a hormone precursor, into the mitochondria and LH-stimulated cAMP production for intracellular signaling [121,124,129,132,134,162]. In light of this evidence, it stands to reason that ageing can reduce testosterone function by mechanisms reducing the T production of the LCs as in hypogonadism [163–165]. Studies reveal that the age-like effects observed in the testes are not due to a decrease in LC count, but rather by a sort of cooperation in the ability of the cells to make T in response to LH that could be resulted by the ‘fitness’ of the associated, local vascular supply caused by blockade or lag in gonadotropin response [148,168]. The ER-A type receptors (ERs-A), are located specifically in the interstitium of the testis, have been found to play a key role in maintaining a differentiated epithelium morphology and to regulate fluid reabsorption in the male reproductive system [32–38]. Once T becomes scarce, its progeny, E2, will decrease resulting in less protective factors and eventual further testicular atrophy. It has been found that deletions or mutations causing impaired aromatase enzyme formation in males has been linked with diminished or even ablated steroidogenesis [30,34–37]. Additionally, a diminished or lack of aromatase not only impairs steroidogenesis, but can also lead to infertility and impaired spermatogenesis [7–10,14,34–37,151,157]. Since spermatogenesis requires proper LC and SC functioning, the lowering E2, stemming from a significant altered aromatase, could be the root of further testicular impairments [159–168]. This preservative role is clearly highlighted in the female reproductive system.

It has been found that the total number of LCs in elderly male, over the age of 60, can decrease to up to 44% [151,157,163,168,170]. Cellular changes include dedifferentiation, decreased amount of smooth endoplasmic reticulum and mitochondria organelles, multinucleation, and a greater number and larger sized Reinke crystalloid inclusions [140–167]. The high oxygen demand established by the abundant mitochondria in LCs places them at increased ischemic risk; these organelles demonstrating variable morphology according to metabolic activity [170–172] and, along with them, the peroxisomes enzymes can be implicated without increasing their catalase marker [173]. These changes in LCs that come about through the natural ageing process in the male reproductive system can compromise the functionality of the cell thus contributing to a decline in estrogen production [163–170].

Other previous investigations showed with morphology, including

immunocytochemistry, the presence of clear and dense-core vesicles and the co-location of several neuropeptides in LCs, making LCs a new member of the diffuse neuroendocrine system [174]. However, studies are yet to come with age changes in this topic.

In the testes, the LCs can be ectopically located, i.e. in the tunica albuginea, the rete testis or the interlobular septa as well as within hyalinized seminiferous tubules or those with advanced atrophy and marked thickening of the tunica propria, i.e. tubules in adult cryptorchid testes, Klinefelter syndrome, and in some other primary hypogonadisms as reported in a most recent contribution [175].

#### 6.2. Leydig cells and aging alcoholism

In older men and in those with chronic alcoholism, LCs, as well as ectopic LCs may show atrophic features [175].

#### 6.3. Leydig cells and Werner's syndrome

Patients suffering from Werner's Syndrome, a known form human progeria, are found to be lacking the gene for the production of WRN, a protein necessary for preventing early onset senescence of tissue. WRN appears to be only induced by E2 and not T; this also makes E2 a protective agent against early senescence of the reproductive system [20]. These findings suggest that a decreased and lack of estrogen can cause progressive, diminished function of the male reproductive system [176].

#### 6.4. Leydig cell tumors

LCs tumors are usually benign [177] even though they involved gonadotrophin perturbations or are irresponsive to gonadotrophin [177–179], often associated with infertility. Estrogen production rates and excretion were 5- to 10-fold elevated in 2 patients studied, but could be entirely accounted for by tumor metabolism of circulating steroids, notably dehydroepiandrosterone sulfate, and, thus E2 and xenoestrogen exposure could participate in LC tumorigenesis [163,177–179].

#### 6.5. Crystalloids of Reinke

In 1896, Reinke [179] reported the rod or corn-shaped CR structures measuring up to 20  $\mu\text{m}$  in the LCs of the human testis. Named after Reinke by others [143–146], he found them as rice-shaped with iron hematoxylin staining preparations. It was then hypothesized accretion to form larger ones, as suggested through electron microscopy observations [1,146–150,154–170,171–189]. In azoospermia, there are cases when no crystalloid can be seen but pigments [190–199] and there are said ‘to be inconsistent among individuals and among the cells of an individual’ [148]. The crystalloids are variable in form and size and are rectilinear. (about 3  $\mu\text{m}$  in width et 20  $\mu\text{m}$  long], with angles that can be sharp or rounded as they are made of macromolecules 5 nm in diameter and evenly spaced of 19 nm, present in highly ordered pattern of internal structure. For other authors [192–194] and, as reported in Ref. [195], the hexagonal lattice has a 24 nm constant. These peculiar inclusions likely relate to LC steroidogenesis because a similar type of crystalloids was detected in the adrenal cortex [192], the ovary LCs [196] and even in human SCs [196] and swine, including the cryptorchid ones [198]. In cases of azoospermia the same LCs contained fatty deposits with initially formed electron-pale deposits that appear like those of cholesterol, as they are electron-lucent [199], thus resembled cholesterol unesterified in the human gallbladder and cystic duct cholesterosis [200,201]. Others, such as in Ref. [202] have classified these LC deposits. Authors have also found ectopic LCs and Reinke crystals relationships, are these deposits formed through normal functions or metabolic defects or/and ageing deposition of proteinaceous residues? [203–205]. When observed with the light microscope,

old human testis samples do not obviously display the crystalloids in the LCs as in mature testes (Fig. 2 A-B and 3 A-B).

## 7. The seminiferous tubules

### 7.1. The Sertoli cells and the blood-testis barrier

These male reproductive, tubular organs have been described long ago, and Sertoli [206,207] (and its recent translated version about rodents [207]), demonstrated how the reproductive maturation of male gonocytes matured in the testis along with large cells, named after Sertoli.

Briefly, these blind-end, highly convoluted tubular ducts of the testes are contained in the interstitium where LC's aggregates located, bordered by a basement membrane lined by one to more myoid cells (smooth muscle-like cells), a loose connective tissue abundantly vascularized, including lymph capillaries [148–152,206–210]. The seminiferous ducts are lined by prominent, somewhat columnar to pyramidal, branching-shaped cells, named Sertoli cells (SCs), bearing an oblong nucleus and large nucleolus body, annulate lamellae, some lipid and pigments deposits along with markers, the Charcot-Böttcher crystalloid deposits. SCs support of the stem cells and proliferating gonocytes and have phagocytic capabilities of capture of spermatid cytoplasmic excessive cytoplasmic pieces before spermiation. SCs were described, reconstructed in 3-D aspects by Sertoli [206] and have been surveyed throughout the vertebrates, including humans [148–152,209–218]. SCs bear multiple alcove-like depressions, viewed in 3-D profiles, where nest the ascending, maturing gonocytes in the adluminal compartment. The gonocytes and progeny, up to spermatids, are attached along SCs via desmosome-like junctions, gap junctions, ectoplasmic specializations and tubulo-bulbar complexes [148–152]. SCs are attached to the basal lamina they make via hemidesmosomes, and to each other by desmosomes, gap junctions, and tight junctions (the essential junction to constitute what is named the 'blood-testis barrier' (or BTB). Altogether, without the gonocytes, SCs constitute the lining of the rete testis ducts joining the efferent ducts outside the testis through the mediastinum testis. This BTB have also an important barrier preventing any autoimmune defects [215–218]. During the normal process of spermatogenesis, the gonocytes as spermatogonia B cross the BTB and reach the adluminal compartment [Stanton, 148–151]. This BTB constitutes a sort of 'dynamic fence' corralling a basal compartment that contains the stem cells, i.e. spermatogonia type Ad (A dark) and type Ap (or A pale) which mitotic activity of the latter one (2n). There, associated with SC's recesses and diffusing factors, SC influence further their maturation during meiosis and further progresses of spermatocytogenesis. The interconnected SC epithelial cells cycled along its topologically-located spiral cargo bays organized to move upwardly the spermatocytes and spermatids until spermiation, via transient changes of the SC cytoskeleton [216–226]. There, the microtubules cytoskeleton seemingly supportive of other adhesive cytoskeletal regulatory proteins (especially claudin 11 [223–228]) are necessary to maintain normal spermatogenesis through the integrity of the BTB, which expression of normal, functional constitutive cytoskeleton and gap junctions (connexin 43 [229]) depend on hormonal influences, including that of E2 associated with other factors [229–237].

However, as noted by investigators, 'the regulatory mechanisms and changes in junctional proteins that allow this translocation step without causing a 'leak' remain poorly understood' [233] even though some recent clarifications have been carried out [228–235].

During puberty, SCs cease to divide and their population appears stable throughout the lifespan of animals and human [149–151,203,208,209], However, with further ageing, SCs decreased size make them less easily recognizable in microscopic anatomy, as young medical students realized, if they had access to aged tissue's histology preparations (Fig. 2 A-B and 3 A-B). Their reduction in size, at first, among the tubules, and number, similarly to LCs, under hormonal

stimuli maintenance, reduced their population with old age [149,215,231], this progressive cell lessening also contributes to the decreasing spermatogenesis through reduced proliferative index of sperm cells have been measured and, thus, ultimately to testis atrophy [148,151,170,192,208,209,215]. Through ageing, the histological and cytologic ultrastructure demonstrated degenerative patterns of organelles architecture, as well as the BTB. SCs can display vacuolization, mitochondria metaplasia, dedifferentiation and even multinucleation [148,150]. SCs maintain the blood-testis barrier (BTB), have a BTB, with its components, the intermediate filament network or tensile structures functions to protect spermatogonia differentiation until the spermiation named for the 'liberation' of the spermatid-spermatozoa gametes leaving the tubule's SCs for the rete testis, and further their maturation in the epididymis [222–224,230].

### 7.2. Intricate hormonal interactions on Sertoli cells, including E2

SCs are not terminally differentiated [218] and express high levels of pro-survival B-cell lymphoma-2 (BCL2) proteins, thus inhibition of apoptosis and autophagic processing and prolongs SC survival upon exposure to stress stimuli [237,238]. SCs respond to a complex ballet performance directed by some hypothalamo-pituitary pulsatile stimuli that interact, especially from acidophil cells [169,239], and, via biological circadian and seasonal cycles in rodents and, perhaps in humans. There, E2 and T, metabolites and alike (iodinated hormones) altogether or in complex interactions modulate the expressing genes via Krüppel-like factors [239–246] for some of the SC's paracrine maintenance of intercellular tight junction's components, or at least they can become potential mediators of junctional assembly and disassembly during the translocation process of the gonocytes by SCs towards the lumen side spermatogenesis and spermatocytogenesis [110,111,114,115,117,125,126,168,169,211–217, 237, 238], including spermiation (see paragraph 5.3.).

Out of the hypothalamus, the gonadotroph FSH release in vivo or in vitro favors aromatase activity and make SCs [247–249] to produce some E2, metabolite derived from T, as found in human [250–252]. FSH acts on SC's maintenance [22,111,112,169] and ERs control proteomics, including aromatase. There. Even if FSH has abnormal level, it does not alter significantly SC morphology [215, 231, 249]. However, prolactin (PRL) in excess can changes the tubule histology, favoring degradation of SCs and the depletion of the seminiferous tubules of germ cells [10,11,253]. For the other cells of the tubules, and maturing gonocytes, it is beta types that have been found in males [30,37,131,211] ubiquitous to almost every cell in the seminiferous tubules. Early data finding E2 in human [251,252], then further studied in KO mice [254] demonstrated that the tall ciliated columnar epithelial cells of the efferent ducts, normally bearing long microvilli undergo metaplasia changes towards smaller, cuboidal shaped cells, with sparse microvilli, thus some atrophic changes without the E2 maintenance of a differentiated status of these duct's epithelium [109,110]. Consequently, E2 (and other cooperative hormones, i.e. androgen binding protein or ABP- see later in 5.2. paragraph) is potentially linked to testicular atrophy correlated with the 'natural' ageing process associated with the E2 body depletion.

Despite E2 and ER-A and -B presence in males, and known deleterious effects of perinatal E2 or DES treatment, there are now arrays of evidences (SCs, spermiation) that E2/ER-A and-B signaling are important in the spermatogenesis and spermiogenesis studied in rodents and, again, probably, in some aspects, in normal human reproduction. Possibly, other longitudinal human studies would provide more information, especially regarding the usage of environmental endocrine perturbators. It is also in this topic that rodent's models, including KO murine, would be important to clarify some aspects noted with poor understanding in human defects [10,11,23,32–34,117,159,238,240,254] then observed in biopsies obtained without creating autoimmune orchitis [255]. Studied throughout vertebrates [203,205,213,214], mostly rodents, including KO mice [e.g. 247, and

6,9, 28, 29, 30–36, 100, 101, 111, 195], made investigators grasp some peculiar and unfamiliar functions of E2 in human [29,38,39,52,102,114–116,215,216,248] and vice versa. These made find in human bear two forms of ER commonly known as  $\alpha$  (ER $\alpha$ , NR3A1) and  $\beta$  (ER $\beta$ , NR3A2) have been cloned from human [117–122, 124, 248, 249]. There, SCs have high levels of ER-A.

BTB maintenance is crucial to testicle's integrity and functions, especially for SC's cytoskeleton, apparently modulated by E2 [247–250] and a series of hormones and factors, that included the secreting pituitary basophils (i.e. gonadotrope FSH [251] and thyrotrope [e.g. triiodothyronine [252] as well as acidophils [growth hormone IGF-1 [253]] and the antagonistic prolactin (PRL [10,11,254]; The developmental anti-Mullerian hormone [255,256], Other testicular factors for differentiation, metabolism (retinoic acid and related factors [258–260]), transport and proteases controlling phagosomes of spermatid maturation and digestion, can modulate SCs via feedback to the pituitary (e.g. transforming growth factor  $\beta$  (TGF $\beta$ , activin A) [257,258], inhibin alpha type [261–263], and even the C-type natriuretic peptide [264]. Simultaneously, in adult and aging, the androgen binding protein (ABP), secreted in the seminiferous tubule lumen with other compounds (i.e. transferrin [265]), maintained the integrity of the inner structures of the tubules [265–269] that could be investigated through selected biopsies [270].

One reiterates that the unclear significant (or awkward?) activity of E2 in human seminiferous tubules have been constrained scientific discussions, yet of biomedical or pathology interests, due to dwindling funding at first, about the DES lesser impact on the afflicted population, and also about animal research used as model for a human potent interest and public health. It is true that the number of male patients involved with DES related pathologies have diminished during the last 25 years, due to infertility [270]. However, xenoestrogens or similar endocrine perturbators currently present in the environment and nutrients apparently as 'safe' additives may generate insinuating diseases, not only in the developing reproductive organs, but could affect public health, thus their investigations should create new regulations and dietetic policies.

### 7.3. Spermiation

This process features an intracellular dynamic, cytoskeletal turnover allowing millions of mature spermatids in late stage VIII in rodents versus late stage II in human [271,272] and 'released from SC into the seminiferous lumen' [272–274]. This turnover and reconstructed cytoskeleton is modulated by E2, metabolites and other factors surveyed in the previous paragraph 5.2.

Again, many of these regulations verified in lower vertebrates and mammals, including human but those have not been considered in ageing [266,267] because evidences show that age significantly decreased the volume of the seminiferous tubules and, for some authors, leaves the interstitium unchanged. However, in most cases, the ageing process, like in Klinefelter syndrome or infertile testes histopathology [192,275–277], some breakdown of the blood-testis barrier induces striking changes in the appearance of Sertoli cells and in their renewal, further enhanced through any other degeneration, including of immune-degenerative induced lesions. This includes the installation of a progressive, histological sclerosis of the tubule tunica propria caused by collagenization (change or modification of population of the lamina propria, diverse lesions in the tubules, including a reduced spermiogenesis (loss of diverse lining cells) [147–152] (Fig. 2 A-B vs Fig. 3A and B).

### 7.4. 4. Crystalloid of Charcot- Böttcher

These fine structures were named after Charcot and Böttcher [278] seen in SCs. Sorts of histologic curiosity, their nature is still unclear even though they seemed to have become markers of the Sertoli cells in

biopsies in young adults, adult fertile or not, and tumor cells even though out of some electron micrographs, their features appeared more like amassed filamentous -intermediate filament-like amassed. The 'crystals' are constituted as 10–25  $\mu$ m in length, spindle-shaped; they stain with eosin with hematoxylin-eosin, Mallory's aniline blue, phosphotungstic acid, tetrazolium compounds and Coomassie brilliant blue. Furthermore, they seem proteinaceous packets viewed with the electron microscope as fascicles made of parallel fibrillar arrays with variable spaces; the fibrils ranged from 9 to 11 nm in width. They appeared in continuity with the intermediate filaments of the perikaryon [278–292]. Some authors described them connected with the nuclear envelope as well as with the rough endoplasmic reticulum. They accompany accumulation of lipid droplets, sometimes poorly developed as 'paracrystalline' [150,152,278–291], also found in marsupials and tree-toes sloths [292]. Are these related to 'aging' germ cells or dysfunction of the maturing cells?

### 7.5. The spermatozoa

The progeny of mitotic spermatogonia differentiates into meiotic spermatocytes, that elongate as spermatids (1n, haploid) under the nursing 'supervision' of SCs [293,298–300] and E2 activity [46–51,125,126,212,213,300,301]. It is without forgetting that gametes since their beginning as spermatogonia are quasi syncytial as they connect with cytoplasmic bridges until spermiation, excising each perikaryon and excessive cytoplasm, making them male motile gametes [147–152,170,294–297,299,300]. ERs type beta (ER-B) receptors (2 types) found in human [125,126,299,301–305]. E2 stimulus appears to favor survival according to in vitro report [306]. Verified in rodents [45–48,307–309] ERs were predominantly located in the pachytene spermatocytes and associated with the midpiece endoplasmic reticulum and their rich mitochondria content location [306]. with the Golgi apparatus of the round spermatids, the spermatid and spermatozoa strictly demonstrated aromatase in the midpiece region, where the main endoplasmic reticulum is localized [e.g. 36, 37, 109–110, 302–303]. Similarly, in rodents, B type spermatogonia are strongly ER-B immune-positive, whereas the highest levels of ex-pression of ER-A are observed in round spermatids [48–51]. In the final stage of spermiation and motility, the flagellum acquires other receptors, including for androgen [309–312,351] and motility regulation is triggered by fibroblast growth factor receptors [313,314].

With old age, the population of altered or aneuploid gametes does not appear different than in young or adult people [152,296,302,303,315]. Many altered chromosomal distribution (aneuploidy), such as in testicle's raised temperature [316] or loss of E2 influence [317] can induce apoptotic death, as seen in man [294–297] or rodents [298–300]. Then, the discharged gametes move or are moved (due to subepithelial, lamina propria musculature) into toward the rete testis toward the epididymis, their ultimate maturity storage where some final maturation occurs, including some cytoplasmic excisions of some, few spermatozoa. There are still large percentage of them with aneuploidy and diverse morphology and anomalies that are unfunctional after ejaculation.

Even though these studies, questions unanswered 'about the 'conflicting findings expression pattern of ER $\alpha$ , ER $\beta$  and androgens' in sperm cells, especially that mitochondria can bear steroid receptors or, at least, sensitive to E2 metabolites, that could modify the changing oxidative metabolism pattern within the germ cell's differentiation. This topic needs further clarifications even though some aspects of degenerative structures were found in human defects [37,151,286,315–318].

#### 7.5.1. Lubarsch deposits, so-called crystals, as spermatogonia markers

Observed with light microscopy by Lubarsch [319,320] and reported in Ref. [278]; then, reviewed with ultrastructure aspects, these 'markers' seemed to be usually recognized as filamentous components aggregated as elongated deposits in spermatogonia



[147–150,152,284,291,315,321,322]. To find out more about these 'markers, whether transient macromolecular smudge or structure and about their nature, specific molecular evidences should investigate the topic.

## 8. Analgesic and contraceptive activities

Some pharmaceutical compounds can influence male fertility [323], and an analgesic such as Ibuprofen have been associated with inducing hypogonadism [324–326]. Use of ibuprofen during fetal life has been shown to suppress transcriptional activity of androgen synthesis within the testes. This loss of function has resulted in testicular atrophy [324–326]. This once again illustrates on one hand, the role androgens, associated with E2, that play in preventing testicular atrophy and on the other hand, some possibility of implications for male contraception before ageing, progressive sort of 'andropause' [327]. Other nutritional additives or frequent fungicides need to be evaluated about public health as they are commonly used and perturb the reproductive system [328,329].

## 9. The myoid cells and interstitium

These peculiar smooth muscles of the interstitium testis, located along the basal laminae of the seminiferous tubule, mentioned above [148–152,206–210,330] were generated by the mesenchyme testis [330,331]. Myoid cells have been shown to bear ERs-A. Interactions between these smooth muscle cells, among the stroma, with Sertoli cells and other connective tissue cells through paracrine and intracrine interactions in rodents [332–334] and other animals (horses) where reproductive and commercial interests have predominated more than scientific value [335]. This detection of E2 receptor type A likely could stimulate interests in the future for being influenced by environmental poisons along with ageing and, thus for indirectly influencing spermiogenesis as perturbations of E2 can contribute to clinical conditions evoked above.

Moreover, if many ancient studies have reported intratesticular nerves and suspected to exert some regulatory effects on the functions of the male gonad, including the seminiferous epithelium and interstitium cell's and tissue's functions. However, quasi all of them included development and are limited to young adult. Close association of testicular nerve fibers with myoid cells of the seminiferous tubules has been shown in rats and humans [331,337–340]. Direct effects of nor-adrenaline and acetylcholine on the contractility of seminiferous tubules have also been evidenced in vitro [337,338] and testicular nerves close to tubules are, therefore, thought to be involved in contraction of seminiferous tubules. In human testes of newborns, adults and the aged are innervated by NPY fibers, which are located in the interstitial compartments and around blood vessels [341–346]. Thus, no adrenergic nerves were detected [346] but peptidergic nerves and immunoreactive to PGP 9.5, NPY and CPON were found running along the tubules. It is possible that neuropeptides, such as NPY and calcitonin gene-related peptide (CGRP), regulate motility similarly to other structures made of non-vascular smooth musculature motion [347,348]. Furthermore, an evident expression of NPY and CPON in the peritubular myoid cells was for the first time detected in their study. This data, obtained with light microscopy could bring question whether the peptide's location should not be verified with fine structure, because of 'en-passant' fine nerve endings could be there instead and the peptide could co-localize with nerve endings of the myoid cells. The interesting data could then be assumed these peptidergic nerves run along the tubule walls could be implicated in contraction of seminiferous tubules in the young adult human testis, devoid of monoaminergic nerves, and could serve as major neuronal regulators for testicular functions at that age. Also, other regulatory signals originated from blood vessels, such as endothelins [349,350], and other signals to discover, to participate in a paracrine control of spermatogenesis cannot yet be ruled out, but

no study has reported data for old males insofar [148–150,206–210,330–342].

Up until today, literature searches mainly notice the understanding of development and deals with diagrammatic autocrine-paracrine-endocrine models that could intervene with aging morphology or translational anatomical data [333,336,344]. The only indication of changes are the ones one has pointed to an atrophy and 'clearing' of stroma content in the seminiferous interstitium [330–333,336] and exemplified in our illustrative figures.

Dealing with microscopic anatomy, one can recognize that the architecture of the lamina propria depicts a continuous smooth muscle layer with increased thickening from the myoid 'upstream' delicate layer of the seminiferous tubules that progresses 'downstream' with the rete testis, efferent ducts, epididymis and deferent ducts. This overall anatomical and functional continuity where innervation and E2 level could 'impregnate' this muscle tissue, regulate maintenance of inter-cellular contacts (gap junctions) and, thus, indeed motility waves during ejaculation, similarly as it is done in female with uterine musculature and one of other peptides, such as oxytocine [348–352].

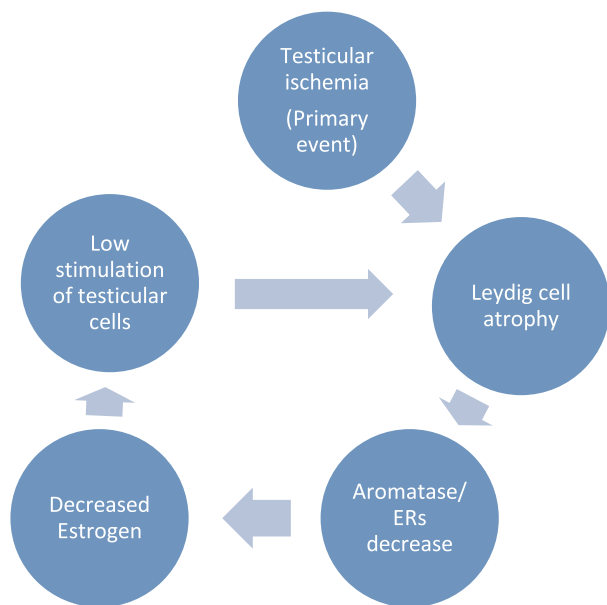
Interactive regulations between seminiferous tubule components SCs with components of interstitial cells (i.e. LCS) and myoid ones, involving maturation and aging have been proposed based on murine models, including for human normal and some defects but yet to be verified morphologically and with aging [350,353,354].

## 10. Clinical aspects and conditions

Declining fertility has been recorded in most industrialized countries, where delayed child bearing is common [355–360]. The progressive decline in man spermatogenesis and reproduction are known with multiple causes in ageing, such as environmental [15–17] and metabolism changes with decreased gonadotropin activities [360–363], growth hormone [362], accumulated reactive oxygen species of lifetime, including adiposity and its adipokines [355,358,364–367]. In some cases, malnutrition [364] and other maladies, such as mumps orchitis accompanied with gynecomastia [367,368] would favor early infertility. There, among pelvic changes [365], vascular defects and varicoceles [367,368]. The decline or loss of physical activity, bearing in mind that some fitness maintenance would assist aged man in his basic health more than inactivity [369,370]. Finally, T supplements have been used [371–374]; let us allow us to remark that if this would call for another subject to write about, athletes and sports competitions do not mix with extra T and other androgens intake as, most of the time and in the long term, they can induce endocrine changes and other serious pathologies including virilism, stroke, heart attack, prostate tumorigenesis, liver and reproductive defects [371–375].

## 11. Concluding remarks

New tools and techniques have enabled tremendous progress in molecular analysis of components that elucidate numerous critical aspects of estrogen signaling in the testis functions and maintenance. Generation of transgenic animals has allowed analysis of the physiological roles of the estrogen-signaling components in biologically relevant models to comprehend that testes have been known to be targets for E2 and metabolites along with those clinical conditions that have also allowed to highlight the farthest boundary on the E2 functional aspects in male gender. Through the biomedical literature dealing with the topic, testicular atrophy and/or dysfunction appears to follow E2 decline [317]; this change could probably follow not only a desensitization or depletion of expressed E2 receptors but a siphoning over-activity of 5 $\alpha$ -reductase away from declining aromatase [50,52] could contribute to other defects in the elderly (i.e. prostate hypertrophy) (Fig. 1). Additionally, some general [375] and local genital ischemia [13,365,375] or faults in lymphatic drainage could also be partially responsible for testicular atrophy (Fig. 4). Perhaps, more



**Fig. 4.** Overactivity of 5- $\alpha$  reductase in BPH as one age could siphon testosterone away from aromatase thus decreasing estrogen production.

fundamentally, as the overall vascular-lymphatic supply fitness declines, the poorly studied pineal relationships with hypothalamo-pituitary-testis axis cycles slow down and clearance of pituitary gonadotropins and other associated components [7,50,169,360–363,375–377] could further influence on the testicle's tissues hormone's and receptor's expressions, as well as some local innervation and signals that are still to be studied [346,354]. All of these factors and interactions could initiate some entropic cascade ahead of testicular ischemia resulting in ageing testicular, reproductive atrophy while sub-mucosal sclerosis installs. Most of the histology and ultrastructural changes reported have demonstrated similar retrograde involution to fit all with what was noted by Ref. [318] and emphasized by Paniagua et al. [150,152] that ‘...there is no definite age at which testicular involution begins, and the onset and severity of testicular lesions are subjected to pronounced individual variations.’ A lesser production of final spermatids follows incomplete differentiation and atrophic changes ensue. Could we suggest that further translational biomedical research studies focus on longitudinal studies on humans ageing to solidify the cause(s) of testicular atrophy.

## 12. Common language with historical connections

Metaphoric word issued from Latin ‘*testiculus*’ (pl. *testiculi*), diminutive of ‘*testis*’ (translated: ‘witness’ out of old French ‘*temoign*’ (about 1150) combining ‘*testimonium*’ (proof) and ‘*testis*’ (a third person of proof’ as of in the ancient Latin Plaute as in the sentence: ‘... Ipse sum testis’; translated: ‘But I am witness’) [378]. Old English had Celtic ‘*beallucas*’ (see the Middle English, *ballockwort* (circa 1300 as in ‘*ballocks*’) and ‘*herþan*’, probably originally “leather bag” (“*heorþa*” = “deer-skin”). The commonest slang terms for them in other languages are words that mean “balls,” “stones,” “nuts,” “eggs.” The slang of “testicles” sense has tended to nudge the word toward taboo territory [379]. Even though, about 75 years ago, December 22, 1944, during the Second World-War Bastogne barricade, a courageous U.S. army commander used it foully against a Nazi messenger requesting surrendering of the Belgian city [380].

## Financial disclosure

Authors do not have any financial disclosure.

## Ethical statement

Ethical statement is considered and described in Materials and Methods.

## Declaration of competing interest

The authors do not have any conflict of interest in this survey.

## Acknowledgements

Authors thanks St George's University School of Medicine, Global Scholar's Program in Newcastle upon Tyne, United Kingdom and the Département de Médecine, Université de Namur, Namur, Belgium for providing illustrations through the laboratory and teaching collections. The authors apologize for authors who were not cited among the huge literature survey accomplished in this topic.

## References

- [1] M. Dym, The male reproductive system. Chapter 28, Leon Weiss New York: Histology- Cell and Tissue Biology, fifth ed., Elsevier Biomedical, 1983, pp. 1000–1053.
- [2] M.H. Ross, W.A. Pawlina, Text and Atlas with Correlated Cell and Molecular Biology, fifth ed., Wolter Kluwer/Lippincott Williams & Wilkins, Baltimore, 2005, pp. 728–771.
- [3] P.C. Champe, R.A. Harvey, D.R. Ferrie, M. Cooper, Biochemistry, fourth ed., Wolters Kluwer/Lippincott Williams & Wilkins, Philadelphia, 2007, pp. 219–244.
- [4] C.R. Stockard, G.N. Papanicolaou, The existence of a typical oestrous cycle in the Guinea-pig -with a study of its histological and physiological changes, *Am. J. Anat.* 22 (1917) 225–283.
- [5] G.N. Papanicolaou, C.R. Stockard, Effect of underfeeding on ovulation and the oestrous rhythm in Guinea-pigs, *J. Reproduct* 17 (1920) 143–144.
- [6] M. Berthrong, W.E. Goodwin, W.W. Scott, Estrogen production by the testis, *J. Clin. Endocrinol. Metab.* 9 (7) (1949) 579–592.
- [7] G.A. Kinson, Pineal factors in the control of testicular function, *Adv. Sex Horm. Res.* 2 (1976) 87–139.
- [8] F.F. Rommerts, A.O. Brinkman, Modulation of steroidogenic activities in testis Leydig cells, *Mol. Cell. Endocrinol.* 21 (1) (1981) 15–28.
- [9] G. Lombardi, S. Zarril, A. Colao, L. Paesano, C. Di Somma, F. Rossi, M. De Rosa, Estrogens and health in males, *Mol. Cell. Endocrinol.* 178 (1–2) (2001) 51–55.
- [10] A. Bartke, H. Klemcke, K. Matt, Effects of physiological and abnormally elevated prolactin levels on the pituitary-testicular axis, *Med. Biol.* 63 (5–6) (1986) 264–272.
- [11] M. De Rosa, S. Zarrilli, A. Di Sarno, N. Milano, M. Gaccione, B. Boggia, G. Lombardi, A. Colao, Hyperprolactinemia in men: clinical and biochemical features and response to treatment, *Endocrine* 20 (1–2) (2003) 75–82.
- [12] S. Zarrilli, G. Lombardi, L. Paesano, C. Di Somma, A. Colao, V. Mirone, M. De Rosa, Hormonal and seminal evaluation of Leydig cell tumour patients before and after orchiectomy, *Andrologia* 32 (3) (2000) 147–154.
- [13] A. Ciccarelli, E. Guerra, M. De Rosa, F. Milone, S. Zarril, G. Lombardi, A. Colao, PRL secreting adenomas in male patients, *Pituitary* 8 (1) (2005) 39–42.
- [14] J.M. Saez, Leydig cells: endocrine, paracrine, and autocrine regulation, *Endocr. Rev.* 15 (5) (1994) 574–626.
- [15] J. Toppari, J.C. Larsen, P. Christiansen, A. Giwercman, P. Grandjean, L.J. jr Guillelte, B. Jégou, T.K. Jensen, P. Jouannet, N. Keiding, H. Leffers, J.A. McLachlan, O. Meyer, J. Müller, E. Rajpert-De Meyts, T. Scheike, R. Sharpe, J. Sumpter, N.E. Skakkebaek, Male reproductive health and environmental xenoestrogens, *Environ. Health Perspect.* 104 (Suppl. 4) (1996) 741–803.
- [16] N.E. Skakkebaek, Testicular dysgenesis syndrome: new epidemiological evidence, *Int. J. Androl.* 27 (2004) 189–191.
- [17] M. Tena-Sempere, E. Aguilar, Biological Effects and Markers of Exposure to Xenosteroids and Selective Estrogen Receptor Modulators (SERMs) at the Hypothalamic-Pituitary Unit, *Hormones and the Brain* © Springer-Verlag Berlin Heidelberg, 2005, pp. 79–98.
- [18] E. Allen, E.A. Doisy, An ovarian hormone, *J. Am. Med. Assoc.* 81 (1923) 819–821.
- [19] A. Butenandt, Über, „Progynon“ ein kristallisiertes weibliches Sexualhormon, *Naturwissenschaften* 17 (45) (1929) 879–879.
- [20] F. Hirschmann, L. Adler Der, Bau des Uterusschleimhaut des geschlechtsreifen Weibes mit besonderer Berücksichtigung den Menstruation, *Mensch. Geburtsch. Gynaekol.* 27 (1928) 1–8.
- [21] B. Zondek, H. von Euler, Follikululin ausscheidung im harn des Kindes, der frau und des mannes, *Skand Arch Physiol* 67 (1934) 259–264.
- [22] V.C. Medvei, A History of Endocrinology, MTP Press Limited, Int Publishers, Lancaster, 1982, pp. 396–435.
- [23] H.J. Coelingh Bennink, C.F. Holinka, E. Diczfalusy, Estetrol review: profile and potential clinical applications, *Climacteric* 11 (Suppl 1) (2008) 47–58.
- [24] <https://bioetymology.blogspot.com/2011/03/estrogen-or-oestrogen.html>.
- [25] H.G. Burger, Androgen production in women, *Fertil. Steril.* 77 (Suppl 4) (2002)

- S3–5.
- [26] A. Au, A. Feher, L. McPhee, A. Jessa, S. Oh, G. Einstein, Estrogens, inflammation and cognition, *Front. Neuroendocrinol.* 40 (2016) 87–100.
- [27] A.M. Aloisi, Why We Still Need to Speak about Sex Differences and Sex Hormones in Pain, *Pain Ther* 6 (2) (2017) 111–114.
- [28] M. Schulster, A.M. Bernie, R. Ramasamy, The role of estradiol in male reproductive function, *Asian J. Androl.* 18 (3) (2016) 435–440.
- [29] A. Vermeulen, J.M. Kaufman, S. Goemaere, I. van Pottelberg, Estradiol in elderly men, *Aging Male* 5 (2) (2002) 98–102.
- [30] B.T. Akingbemi, Estrogen regulation of testicular function, *Reprod. Biol. Endocrinol.* 27 (2005) 3–51.
- [31] K. Kula, R. Walczak-Jedrzejowska, J. Słowikowska-Hilczler, J.K. Wrancic, P. Kula, E. Oszukowska, K. Marchlewska, [Important functions of estrogens in men-breakthrough in contemporary medicine], *Przegl. Lek.* 62 (9) (2005) 908–915 (In Polish).
- [32] R.A. Hess, Estrogen in the adult male reproductive tract: a review, *Reprod. Biol. Endocrinol.* 1 (52) (2003) 1–14.
- [33] R.A. Hess, Estrogen in the adult male: from a curiosity to absolute necessity, *Ann. Rev. Biomed. Sci.* 6 (2004) 1–12.
- [34] R.A. Hess, K. Carnes, The role of estrogen in testis and the male reproductive tract: a review and species comparison, *Anim. Reprod.* 1 (2004) 5–30.
- [35] J.E. Sieren, S.F. Sneddon, F. Collins, M.R. Millar, P.T. Saunders, Estrogens in testis biology, *Ann. N. Y. Acad. Sci.* 1061 (2005) 65–76.
- [36] P.S. Cooke, N.K. Nanjappa, C. Ko, G.S. Prins, R.A. Hess, Estrogens in male physiology, *Physiol. Rev.* 97 (3) (2017) 995–1043.
- [37] A. Hess, P. Cooke, Estrogen in the male: a historical perspective, *Biol. Reprod.* 99 (1) (2018) 27–44 2018.
- [38] A.H. Payne, R.P. Kelch, S.S. Musich, M.E. Halpern, Intratesticular site of aromatization in the human, *J. Clin. Endocrinol. Metab.* 42 (1976) 1081–1087.
- [39] L.S. Marks, 5 $\alpha$ -reductase: history and clinical importance, *Rev. Urol.* 6 (Suppl 9) (2004) S11–21.
- [40] S. Lambard, D. Silandre, C. Delalande, I. Denis-Galeraud, S. Bourguiba, S. Carreau, Aromatase in testis: expression and role in male reproduction, *J. Steroid Biochem. Mol. Biol.* 95 (1–5) (2005) 63–69.
- [41] S.A. Chen, M.J. Besman, R.S. Sparkes, S. Zollman, I. Klisak, T. Mohandas, P.F. Hall, J.E. Shively, Human aromatase: cDNA cloning, Southern blot analysis, and assignment of the gene to chromosome 15, *DNA* 7 (1) (1988) 27–38.
- [42] M.S. Mahendroo, C.R. Mendelson, E.R. Simpson, Tissue-specific and hormonally controlled alternative promoters regulate aromatase cytochrome P450 gene expression in human adipose tissue, *J. Biol. Chem.* 268 (26) (1993) 19463–19470.
- [43] S.E. Bulun, S. Sebastian, K. Takayama, T. Suzuki, H. Sasano, M. Shozu, The human CYP19 (aromatase P450) gene: update on physiologic roles and genomic organization of promoters, *J. Steroid Biochem. Mol. Biol.* 86 (3–5) (2003) 219–224.
- [44] K. Golovine, M. Schwerin, J. Vanselow, Three different promoters control expression of the aromatase cytochrome p450 gene (*cyp19*) in mouse gonads and brain, *Biol. Reprod.* 68 (3) (2003) 978–984.
- [45] I. Czajka-Oraniec, E.R. Simpson, Aromatase research and its clinical significance, *Endokrynol. Pol.* 61 (1) (2010) 126–134.
- [46] M.L. Meistrich, M. Kangasniemi, Hormone treatment after irradiation stimulates recovery of rat spermatogenesis from surviving spermatogonia, *J. Androl.* 18 (1) (1997) 80–87.
- [47] P. Singh, L.M. Aggarwa, S.A. Parry, M.J. Raman, Radiation dosimetry and repair kinetics of DNA damage foci in mouse pachytene spermatocyte and round spermatid stages, *Mutagenesis* 33 (3) (2018) 231–239.
- [48] L. O'Donnell, K.M. Robertson, M.E. Jones, E.R. Simpson, Estrogen and spermatogenesis, *Endocr. Rev.* 22 (3) (2001) 289–318.
- [49] R.I. McLachlan, L. O'Donnell, P.G. Stanton, G. Balourdos, M. Frydenberg, D.M. de Kretser, D.M. Robertson, Effects of testosterone plus medroxyprogesterone acetate on semen quality, reproductive hormones, and germ cell populations in normal young men, *J. Clin. Endocrinol. Metab.* 87 (2) (2002) 546–556.
- [50] K.L. Matthiesson, R.I. McLachlan, L. O'Donnell, M. Frydenberg, D.M. Robertson, P.G. Stanton, S.J. Meachem, The relative roles of follicle-stimulating hormone and luteinizing hormone in maintaining spermatogonial maturation and spermiogenesis in normal men, *J. Clin. Endocrinol. Metab.* 91 (10) (2006) 3962–3969.
- [51] L. O'Donnell, K. Pratis, A. Wagenfeld, U. Gottwald, J. Müller, G. Leder, R.I. McLachlan, P.G. Stanton, Transcriptional profiling of the hormone-responsive stages of spermatogenesis reveals cell-, stage-, and hormone-specific events, *Endocrinology* 150 (11) (2009) 5074–5084.
- [52] L.R. Axelrod, Metabolic patterns of steroid biosynthesis in young and aged human testes, *Biochim. Biophys. Acta* 97 (3) (1965) 551–556.
- [53] C.M. Szego, J.S. Davis, Adenosine 3',5'-monophosphate in rat uterus: acute elevation by estrogen, *Proc. Natl. Acad. Sci. U. S. A.* 58 (4) (1967) 1711–1718.
- [54] B.W. O'Malley, W.I. McGuire, Studies on the mechanism of estrogen-mediated tissue differentiation: regulation of nuclear transcription and induction of new RNA species, *Proc. Natl. Acad. Sci. U.S.A.* 60 (4) (1968) 1527–1534.
- [55] C.S. Rosenfeld, P.S. Cooke, Endocrine disruption through membrane estrogen receptors and novel pathways leading to rapid toxicological and epigenetic effects, *J. Steroid Biochem. Mol. Biol.* 187 (2019) 106–117.
- [56] J. Gilloteaux, A.W. Steggle, Alterations in Hamster uterine catalase levels as a result of estrogen treatment. A histochemical analysis, *Ann. N. Y. Acad. Sci.* 386 (1982) 546–548.
- [57] J. Gilloteaux, R.J. jr Paul, A.W. Steggle, Upper genital tract abnormalities in the Syrian hamster as a result of in utero exposure to diethylstilbestrol. I. Uterine cystadenomatous papilloma and hypoplasia, *Virchow's Archiv Anat Pathol A* 398 (1982) 163–183.
- [58] L.B. Hendry, Stereochemical complementarity of DNA and steroid agonists and antagonists, *J. Steroid Biochem.* 31 (4B) (1988) 493–523.
- [59] L.B. Hendry, T.G. Muldoon, V.B. Mahesh, The metabolic pathways for hormonal steroids appear to be reflected in the stereochemistry of DNA, *J. Steroid Biochem. Mol. Biol.* 42 (7) (1992) 659–670.
- [60] S.A. Adeoya-Osiguwa, S. Markoulaki, V. Pocock, S.R. Milligan, L.R. Fraser, 17 $\beta$ -Estradiol and environmental estrogens significantly affect mammalian sperm function, *Hum. Reprod.* 18 (1) (2003) 100–107.
- [61] M. Adlanmerini, R. Solinhac, A. Abot, A. Fabre, I. Raymond-Letron, A.L. Guihot, F. Boudou, L. Sautier, E. Vessières, S.H. Kim, P. Lière, C. Fontaine, A. Krust, P. Chambon, A. Katzenellenbogen, P. Gourdy, P.W. Shaul, D. Henrion, J.F. Arnal, F. Lenfant, Mutation of the palmitoylation site of estrogen receptor  $\alpha$  in vivo reveals tissue-specific roles for membrane versus nuclear actions, *Proc. Natl. Acad. Sci. U. S. A.* 111 (2) (2014) E283–E290.
- [62] R.T. Mitchell, R.M. Sharpe, R.A. Anderson, C. McKinnell, S. Macpherson, L.B. Smith, W.H. Wallace, C.J. Kelnar, S. van den Driesche, Diethylstilboestrol exposure does not reduce testosterone production in human fetal testis xenografts, *PLoS One* 8 (4) (2013) e61726.
- [63] M. Beato, P. Herrlich, G. Schütz, Steroid hormone receptors: many actors in search of a plot, *Cell* 83 (1995) 851–857.
- [64] M.G. Parker, R. White, Nuclear receptors spring into action, *Nat. Struct. Biol.* 3 (2) (1996) 113–115.
- [65] M.G. Parker, R. White, Molecular mechanisms of steroid hormone action, *Endocr. Relat. Canc.* 5 (1998) 1–14.
- [66] B. Gondos, C.A. Egli, S.M. Rosenthal, M.M. Grumbach, Testicular changes in gonadotropin-independent familial male sexual precocity. Familial testotoxicosis, *Arch. Pathol. Lab. Med.* 109 (11) (1985) 990–995.
- [67] M. Fukami, M. Miyado, K. Nagasaki, M. Shozu, T. Ogata, Aromatase excess syndrome: a rare autosomal dominant disorder leading to pre- or peri-pubertal onset gynecomastia, *Pediatr. Endocrinol. Rev.* 11 (3) (2014) 298–305.
- [68] D.I. Spratt, J.R. Morton, R.S. Kramer, S.W. Mayo, C. Longcope, C.P. Vary, Increases in serum estrogen levels during major illness are caused by increased peripheral aromatization, *Am. J. Physiol. Endocrinol. Metab.* 291 (3) (2006) E631–638.
- [69] A.J. Ellis, V.M. Hendrick, R. Williams, B.S. Komm, Selective estrogen receptor modulators in clinical practice: a safety overview, *Expert Opin. Drug Saf.* 14 (6) (2015) 921–934.
- [70] B. Ludwikowski, S. Heger, N. Datz, A. Richter-Unruh, R. González, Aromatase deficiency: rare cause of virilization, *Eur. J. Pediatr. Surg.* 23 (5) (2013) 418–422.
- [71] N. Bouchoucha, D. Samara-Boustani, A.V. Pandey, H. Bony-Trifunovic, G. Hofer, Y. Aigrain, M. Polak, C.E. Flück, Characterization of a novel CYP19A1 (aromatase) R192H mutation causing virilization of a 46,XX newborn, undervirilization of the 46,XY brother, but no virilization of the mother during pregnancies, *Mol. Cell. Endocrinol.* 390 (1–2) (2014) 8–17.
- [72] E. Unal, R. Yildirim, F.F. Taş, V. Demir, H. Onay, Y.K. Haspolat, Aromatase deficiency due to a novel mutation in CYP19A1 gene, *J Clin Res Pediatr Endocrinol* 10 (4) (2018) 377–381.
- [73] Y. Sato, T. Tando, M. Morita, K. Miyamoto, T. Kobayashi, R. Watanabe, T. Oike, M. Matsumoto, M. Nakamura, T. Miyamoto, Selective estrogen receptor modulators and the vitamin D analogue eldcalcitol block bone loss in male osteoporosis, *Biochem. Biophys. Res. Commun.* 482 (4) (2017) 1430–1436.
- [74] S. Chen, S.R. Oh, S. Phung, G. Hur, J.J. Ye, S.L. Kwok, G.E. Shrode, M. Belury, L.S. Adams, D. Williams, Anti-aromatase activity of phytochemicals in white button mushrooms (*Agaricus bisporus*), *Canc. Res.* 66 (24) (2006) 12026–12034.
- [75] M.J. Balunas, B. Su, R.W. Brueggemeier, A.D. Kinghorn Ad, Natural products as aromatase inhibitors, *Anti Canc. Agents Med. Chem.* 8 (6) (2008) 646–682.
- [76] J. Zhao, A.K. Dasmahapatra, S.I. Khan, I.A. Khan, Anti-aromatase activity of the constituents from damiana (*Turnera diffusa*), *J. Ethnopharmacol.* 120 (3) (2008) 387–393.
- [77] K. Szewczyka, C. Zidorn, Ethnobotany, phytochemistry, and bioactivity of the genus *Turnera* (Passifloraceae) with a focus on damiana -*Turnera diffusa*, *J. Ethnopharmacol.* 152 (3) (2014) 424–443.
- [78] M. De Rosa, S. Zarrilli, L. Paesano, U. Carbone, B. Boggia, M. Petretta, A. Maisto, F. Cimmino, G. Puca, A. Colao, G. Lombardi, Traffic pollutants affect fertility in men, *Hum. Reprod.* 18 (5) (2003) 1055–1061.
- [79] S. Richard, S. Moslemi, H. Sipahutar, N. Benachour, G.E. Seralini, Differential effects of glyphosate and roundup on human placental cells and aromatase, *Environ. Health Perspect.* 113 (6) (2005) 716–720.
- [80] N. Benachour, H. Sipahutar, S. Moslemi, C. Gasnier, C. Travert, G.E. Seralini, Time- and dose-dependent effects of roundup on human embryonic and placental cells, *Arch. Environ. Contam. Toxicol.* 53 (1) (2007) 126–133.
- [81] C. Gasnier, C. Dumont, N. Benachour, E. Clair, M.C. Chagnon, G.E. Seralini, Glyphosate-based herbicides are toxic and endocrine disruptors in human cell lines, *Toxicology* 262 (3) (2009) 184–191.
- [82] R.M. Romano, M.A. Romano, M.M. Bernardi, P.V. Furtado, C.A. Oliveira, Prepubertal exposure to commercial formulation of the herbicide glyphosate alters testosterone levels and testicular morphology, *Arch. Toxicol.* 84 (4) (2010) 309–317.
- [83] M.A. Romano, R.M. Romano, L.D. Santos, P. Wisniewski, D.A. Campos, P.B. de Souza, P. Viau, M.M. Bernardi, M.T. Nunes, C.A. de Oliveira, Glyphosate impairs male offspring reproductive development by disrupting gonadotropin expression, *Arch. Toxicol.* 86 (4) (2012) 663–673.
- [84] M. Kwiatkowska, J. Paweł, B. Bukowska, [Glyphosate and its formulations—toxicity, occupational and environmental exposure], *Med. Pr.* 64 (5) (2013) 717–729 (submitted for publication).
- [85] E. Cassault-Meyer, S. Gress, G.E. Seralini, I. Galeraud-Denis, An acute exposure to glyphosate-based herbicide alters aromatase levels in testis and sperm nuclear quality, *Environ. Toxicol. Pharmacol.* 38 (1) (2014) 131–140.

- [86] N. Defarge, E. Takács, V.L. Lozano, R. Mesnage, J. Spiroux de Vendômois, G.E. Séralini, A. Székács, Co-Formulants in glyphosate-based herbicides disrupt aromatase activity in human cells below toxic levels, *Int. J. Environ. Res. Publ. Health* 13 (3) (2016) 1–17, <https://doi.org/10.3390/ijerph13030264> pii: E264.
- [87] J.P. Myers, M.N. Antoniou, B. Blumberg, L. Carroll, T. Colborn, L.G. Everrett, M. Hansen, P.J. Landrigan, B.P. Lanphear, R. Mesnage, L.N. Vandenberg, F.S. Vom Saal, W.V. Welshons, C.M. Benbrook, Concerns over use of glyphosate-based herbicides and risks associated with exposures: a consensus statement, *Environ. Health* 15 (2016) 19, <https://doi.org/10.1186/s12940-016-0117-0>.
- [88] B. Mao, M. Li, M. Yan, Q. Liana, R. Ge, C. Yan Cheng, Environmental toxicants and cell polarity in the testis, *Reprod. Toxicol.* 81 (2018) 253–258.
- [89] W.W. Greulich, T.H. Hurford, Testicular tumors associated with mammary, prostatic, and other changes in cryptorchid dogs, *Am. J. Canc.* 28 (3) (1936) 496–511.
- [90] C. Huggins, P.V. Moulder, Estrogen production by Sertoli cell tumors of the testis, *Canc. Res.* 5 (1945) 510–514.
- [91] G. Teilmann, Estrogen-producing Sertoli cell tumors (androblastoma tubulare lipoides) of the human testis and ovary; homologous ovarian and testicular tumors, *J. Clin. Endocrinol. Metab.* 9 (4) (1949) 301–318.
- [92] J.J. Staffieri, H. Badano, G. Celoria, Study of testicular estrogenic production in normal individuals and in patients with various alterations of the seminiferous tube, *Rev. Iber. Endocrinol.* 12 (1965) 85–93.
- [93] D. Adamopoulos, D.M. Lawrence, P. Vassilopoulos, N. Kapolla, L. Kontogeorgos, H.H. McGarrigle, Hormone levels in the reproductive system of normospermic men and patients with oligospermia and varicocele, *J. Clin. Endocrinol. Metab.* 59 (3) (1984) 447–452.
- [94] A. McLachlan Ja, R.R. Newbold, B. Bullock, Reproductive tract lesions in male mice exposed prenatally to diethylstilbestrol, *Science* 190 (4218) (1975) 991–992.
- [95] M. Bibbo, W.B. Gill, F. Azizi, R. Blough, V.S. Fang, R.L. Rosenfield, G.F. Schumacher, K. Sleeper, M.G. Sonek, G.L. Wied, Follow-up study of male and female offspring of DES-exposed mothers, *Obstet. Gynecol.* 49 (1977) 1–8.
- [96] W.B. Gill, F.B. Schumacher, M. Bibo, F.H. Straus, H.W. Schoenberg, Association of diethylstilbestrol exposure in utero with cryptorchidism, testicular hypoplasia and semen abnormalities, *J. Urol.* 122 (1) (1979) 36–39.
- [97] R. Singer, M. Sagiv, S. Bruchis, M. Barnett, H. Kaufman, C. Servadio, Total and free testosterone and estradiol in human semen, *Int. J. Fertil.* 32 (1987) 145–148.
- [98] J.H. Dorrington, D.T. Armstrong, Follicle-stimulating hormone stimulates estradiol-17beta synthesis in cultured Sertoli cells, *Proc. Natl. Acad. Sci. U.S.A.* 72 (7) (1975) 2677–2681.
- [99] W.B. Neaves, L. Johnson, J.C. Porter, C.R. jr Parker, C.S. Petty, Leydig cell numbers, daily sperm production, and serum gonadotropin levels in aging men, *J. Clin. Endocrinol. Metab.* 59 (4) (1984) 756–763.
- [100] S. Carreau, S. Lambard, C. Delalande, I. Denis-Galeraud, B. Bilinska, S. Bourguiba, Aromatase expression and role of estrogens in male gonad: a review, *Reprod. Biol. Endocrinol.* 1 (1) (2003) 35.
- [101] S. Carreau, C. Delalande, D. Silandre, S. Bourguiba, S. Lambard, Aromatase and estrogen receptors in male reproduction, *Mol. Cell. Endocrinol.* 246 (1) (2006) 65–68.
- [102] S. Carreau, C. de Vienne, I. Galeraud-Denis, Aromatase and estrogens in man reproduction: a review and latest advances, *Adv. Med. Sci.* 53 (2) (2008) 139–144.
- [103] S. Carreau, S. Wolczynski, I. Galeraud-Denis, Aromatase, oestrogens and human male reproduction, *Philos. Trans. R. Soc. Lond. B Biol. Sci.* 365 (1546) (2010) 1571–1579.
- [104] O.M. Echeverría, A.G. Maciel, A.M. Traish, H.H. Wotiz, E. Ubaldo, G.H. Vázquez-Nin, Immuno-electron microscopic localization of estradiol receptor in cells of male and female reproductive and non-reproductive organs, *Biol. Cell.* 81 (3) (1994) 257–265.
- [105] W.M. van Beurden-Lamers, A.O. Brinkmann, E. Mulder, H.J. van der Molen, High-affinity binding of oestradiol-17beta by cytosols from testis interstitial tissue, pituitary, adrenal, liver and accessory sex glands of the male rat, *Biochem. J.* 140 (3) (1974) 495–502.
- [106] E. Mulder, W.M. van Beurden-Lamers, W. De Boer, A.O. Brinkman, H.J. van der Molen, Testicular estradiol receptors in the rat, *Curr. Top. Mol. Endocrinol.* 1 (1974) 343–355.
- [107] J.B. Murphy, R.C. Emmott, L.L. Hicks, P.C. Walsh, Estrogen receptors in the human prostate, seminal vesicle, epididymis, testis, and genital skin: a marker for estrogen-responsive tissues? *J. Clin. Endocrinol. Metab.* 50 (5) (1980) 938–948.
- [108] S. Mosselman, J. Polman, R. Dijkema, ER beta: identification and characterization of a novel human estrogen receptor, *FEBS Lett.* 392 (1996) 49–53.
- [109] E. Enmark, M. Peltö-Huikko, K. Grandien, S. Lagercrantz, J. Lagercrantz, G. Fried, M. Nordenskjöld, J.A. Gustafsson, Human estrogen receptor beta-gene structure, chromosomal localization, and expression pattern, *J. Clin. Endocrinol. Metab.* 82 (1997) 4258–4265.
- [110] T.J. Durkee, M. Mueller, M. Zinaman, Identification of estrogen receptor protein and messenger ribonucleic acid in human spermatozoa, *Am. J. Obstet. Gynecol.* 178 (6) (1998) 1288–1297.
- [111] E.M. Eddy, T.F. Washburn, D.O. Bunch, E.H. Goulding, B.C. Gladen, D.B. Lubahn, K.S. Korach, Targeted disruption of the estrogen receptor gene in male mice causes alteration of spermatogenesis and infertility, *Endocrinology* 137 (1996) 4796–4805.
- [112] D. Mahato, E.H. Goulding, K.S. Korach, E.M. Eddy, Estrogen receptor- $\alpha$  is required by the supporting somatic cells for spermatogenesis, *Mol. Cell. Endocrinol.* 178 (1) (2001) 57–63.
- [113] G. Delbès, C. Duquenne, J. Szenker, J. Taccoen, R. Habert, C. Levacher, Developmental changes in testicular sensitivity to estrogens throughout fetal and neonatal life, *Toxicol. Sci.* 99 (1) (2007) 234–243.
- [114] G. Pelletier, M. El-Alfy, Immunocytochemical localization of estrogen receptors alpha and beta in the human reproductive organs, *J. Clin. Endocrinol. Metab.* 85 (2000) 4835–4840.
- [115] V. Pentikainen, K. Erkkila, L. Suomalainen, M. Parvinen, L. Dunkel, Estradiol acts as a germ cell survival factor in the human testis in vitro, *J. Clin. Endocrinol. Metab.* 85 (2000) 2057–2067.
- [116] A.H. Taylor, F. Al-Azzawi, Immunolocalisation of oestrogen receptor beta in human tissues, *J. Mol. Endocrinol.* 24 (2000) 145–155.
- [117] L. O'Donnell, K.M. Robertson, M.F. Jones, E.R. Simpson, Estrogen and spermatogenesis, *Endocr. Rev.* 22 (2001) 289–318.
- [118] S. Denger, G. Reid, H. Brand, M. Kos, F. Gannon, Tissue-specific expression of human ERalpha and ERbeta in the male, *Mol. Cell. Endocrinol.* 178 (2001) 155–160.
- [119] S. Makinen, S. Makela, Z. Weihua, Z.M. Warner, B. Rosenlund, S. Salmi, O. Hovatta, J.K. Gustafsson, Localization of oestrogen receptors alpha and beta in human testis, *Mol. Hum. Reprod.* 7 (2001) 497–503.
- [120] P.T. Saunders, R.M. Sharpe, K. Williams, S. Macpherson, H. Urquart, D.S. Irvine, M.R. Millar, Differential expression of oestrogen receptor alpha and beta proteins in the testes and male reproductive system of human and non-human primates, *Mol. Hum. Reprod.* 7 (2001) 227–236, <https://doi.org/10.1093/molehr/7.3.227>.
- [121] R.I. McLachlan, L. O'Donnell, S.J. Meachem, P.G. Stanton, D.M. de Kretser, K. Pratis, D.M. Robertson, Hormonal regulation of spermatogenesis in primates and man: insights for development of the male hormonal contraceptive, *J. Androl.* 23 (2002) 149–162 2002.
- [122] P.T. Saunders, M.R. Millar, S. Macpherson, D.S. Irvine, N.P. Groome, L.R. Evans, R.M. Sharpe, G.A. Scobie, ERbeta1 and the ERbeta2 splice variant (ERbeta2x/beta2) are expressed in distinct cell populations in the adult human testis, *J. Clin. Endocrinol. Metab.* 87 (2002) 2706–2715.
- [123] L.A. Favorito, A.G. Cavalcante, W.S. Costa, Anatomic aspects of epididymis and tunica vaginalis in patients with testicular torsion, *Int. Braz. J. Urol.* 30 (5) (2004) 420–424.
- [124] J.E. Sierens, J.S.F. Sneddon, F. Collins, M.R. Millar, P.T. Saunders, Estrogens in testis biology, *Ann. N. Y. Acad. Sci.* 1061 (2005) 65–76.
- [125] S. Solakidi, A.M. Psarra, S. Nikolopoulos, C.E. Sekeris, Estrogen receptors alpha and beta (ERalpha and ERbeta) and androgen receptor (AR) in human sperm: localization of ERbeta and AR in mitochondria of the midpiece, *Hum. Reprod.* 20 (2005) 3481–3487.
- [126] V. Rago, L. Siciliano, S. Aquila, A. Carpino, Defection of estrogen receptors ER-alpha and ER-beta in human ejaculated immature spermatozoa with excess residual cytoplasm, *Reprod. Biol. Endocrinol.* 17 (2006) 4–36.
- [127] V. Rago, F. Romeo, F. Giordano, A. Ferraro, S. Ando, A. Carpino, Identification of ERbeta1 and ERbeta2 in human seminoma, in embryonal carcinoma and in their adjacent intratubular germ cell neoplasia, *Reprod. Biol. Endocrinol.* 7 (2009) 56, <https://doi.org/10.1186/1477-7827-7-56>.
- [128] V. Rago, F. Romeo, F. Giordano, M. Maggolini, A. Carpino, Identification of the estrogen receptor GPER in neoplastic and non-neoplastic human testes, *Reprod. Biol. Endocrinol.* 9 (2011) 135, <https://doi.org/10.1186/1477-7827-9-135>.
- [129] A. Chimento, R. Sirianni, I. Casaburi, V. Pezzi, Role of estrogen receptors and g protein-coupled estrogen receptor in regulation of hypothalamus-pituitary-testis axis and spermatogenesis, *Front. Endocrinol.* 5 (2014) 1, <https://doi.org/10.3389/fendo.2014.00001>.
- [130] A. Chimento, I. Casaburi, M. Bartucci, M. Patrizii, R. Dattilo, P. Avena, S. Andò, V. Pezzi, R. Sirianni, Selective GPER activation decreases proliferation and activates apoptosis in tumor Leydig cells, *Cell Death Dis.* 4 (2013), <https://doi.org/10.1038/cddis.2013.275> 8 e7.
- [131] S. Carreau, R.A. Hess, Oestrogens and spermatogenesis, *Philos. Trans. R. Soc. Lond. B Biol. Sci.* 365 (1546) (2010) 1517–1535.
- [132] A. Chimento, I. Casaburi, M. Bartucci, M. Patrizii, R. Dattilo, P. Avena, S. Andò, V. Pezzi, R. Sirianni, Selective GPER activation decreases proliferation and activates apoptosis in tumor Leydig cells, *Cell Death Dis.* 4 (2013) e747, <https://doi.org/10.1038/cddis.2013.275>.
- [133] A. Chimento, R. Sirianni, I. Casaburi, V. Pezzi, GPER signaling in spermatogenesis and testicular tumors, *Front. Endocrinol.* 5 (2014) 30, <https://doi.org/10.3389/fendo.2014.00030> eCollection 2014. Review.
- [134] A. Chimento, R. Sirianni, I. Casaburi, V. Pezzi, Role of estrogen receptors and G protein-coupled estrogen receptor in regulation of hypothalamus-pituitary-testis axis and spermatogenesis, *Front. Endocrinol.* 5 (2014) 1–9, <https://doi.org/10.3389/fendo.2014.00001>.
- [135] A. Gopalan, D. Dhall, S. Olgac, S.W. Fine, J.E. Korkola, J. Houldsworth, R.S. Chaganti, G.J. Bosl, V.E. Reuter, S.K. Tickoo, Testicular mixed germ cell tumors: a morphological and immunohistochemical study using stem cell markers, OCT3/4, SOX2 and GDF3, with emphasis on morphologically difficult-to-classify areas, *Mod. Pathol.* 22 (8) (2009) 1066–1074.
- [136] L. O'Donnell, K. Pratis, A. Wagenfeld, U. Gottwald, J. Müller, G. Leder, R.I. McLachlan, P.G. Stanton, Transcriptional profiling of the hormone-responsive stages of spermatogenesis reveals cell-, stage-, and hormone-specific events, *Endocrinology* 150 (11) (2009) 5074–5084.
- [137] P.K. Nicholls, C.A. Harrison, K.L. Walton, R.I. McLachlan, L. O'Donnell, P.G. Stanton, Hormonal regulation of Sertoli cell micro-RNAs at spermiation, *Endocrinology* 152 (4) (2011) 1670–1683.
- [138] C.P. Pavlovich, P. King, M. Goldstein, P.N. Schlegel, Evidence of a treatable endocrinopathy in infertile men, *J. Urol.* 165 (2001) 837–841.
- [139] S. Das, Peyronie's disease: excision and autografting with tunica vaginalis, *J. Urol.* 124 (6) (1980) 818–819.
- [140] F.A. Lopez-Maramba, J.M. Hutson, The relationship between the testis and tunica vaginalis changes with age, *J. Pediatr. Surg.* 50 (12) (2015) 2075–2077.
- [141] Federative International Committee on Anatomical Terminology (FICAT), Wolters

- Kluwer- Lippincott Williams & Wilkins, Philadelphia, 2006.
- [142] F. von Leydig, *Zür Anatomie der männlichen Geschlechtsorgane und Analdrüsen der Säugethiere*, *Zeitschr wiss Zool* 2 (1850) 1–57.
- [143] C. Regaud, *Etudes sur la structure des tubes séminifères et sur la spermatogenèse chez les Mammifères*, *Arch Anat Microsc* 4 (1901) 101.
- [144] P. Bouin, P. Ancel, *Recherches sur les cellules interstitielles du testicule des mammifères*, *Arch. Zool. Exp. Gen.* 1 (1903) 437–523.
- [145] H.V. Winiwarter, Cytological observations on the interstitial cells of the human testis, *Anat. Anzeiger* 41 (1912) 309–320 ([in French]).
- [146] S.G. Haider, Cell biology of Leydig cells in the testis, *Int. Rev. Cytol.* 233 (2004) 181–241.
- [147] D.W. Fawcett, M.H. Burgos, Studies on the fine structure of the mammalian testis. II. The human interstitial tissue, *Am. J. Anat.* 107 (3) (1960) 245–269.
- [148] L.D. Russell, R.A. Ettlin, A.P. Sinha Hikim, E.D. Clegg, *Histological and Histopathological Evaluation of the Testis*, Cache River Press, Clearwater, FL, 1990 ISBN 0-9627422-0-1.
- [149] J.B. Kerr, Ultrastructure of the seminiferous epithelium and intertubular tissue of the human testis, *J. Electron. Microsc. Tech.* 19 (2) (1991) 215–240.
- [150] R. Paniagua, M. Nistal, F.J. Sáez, B. Fraile, Ultrastructure of the aging human testis, *J. Electron. Microsc. Tech.* 19 (2) (1991) 241–260.
- [151] H. Jiang, W. Zhu, J. Li, Q.J. Chen, W.B. Liang, Y.Q. Gu, Quantitative histological analysis and ultrastructure of the aging human testis, *Int. Urol. Nephrol.* 46 (5) (2014) 879–885.
- [152] R. Paniagua, P. Amat, M. Nistal, *Ultrastructure of the Human Testis from Birth to Senility*, Scientific Res Publishing, Inc., 2017 ISBN: 978-1-61896-392-5.
- [153] A.H. Baille, Further observations on the growth and histochemistry of Leydig tissue in the postnatal prepubertal mouse testis, *J. Anat.* 98 (1964) 403–418.
- [154] E. Yamada, Some observations on the fine structure of the interstitial cell in the human testis as revealed by electron microscopy, *Gunma Symp. Endocrinol.* 2 (1965) 1–17.
- [155] B.R. Zirkin, V. Papadopoulos, Leydig cells: formation, function, and regulation, *Biol. Reprod.* 99 (1) (2018) 1–111.
- [156] H. Chen, Y. Wang, R. Ge, B.R. Zirkin, Leydig cell stem cells: identification, proliferation and differentiation, *Mol. Cell. Endocrinol.* 445 (2017) 65–73.
- [157] E.R. Cooper, The histology of the retained testis in the human subject at different ages, and its comparison with the scrotal testis, *J. Anat.* 64 (1) (1929) 5–27.
- [158] H. Chen, M.P. Hardy, I. Huhtaniemi, B.R. Zirkin, Age-related decreased Leydig cell testosterone production in the Brown Norway rat, *J. Androl.* 15 (1994) 551–557.
- [159] C. Wang, A. Leung, A.P. Sinha-Hikim, Reproductive aging in the male brown-Norway rat: a model for the human, *Endocrinology* 133 (1993) 2773–2781.
- [160] I.A. Olesen, U.N. Joensen, J.H. Petersen, K. Almstrup, E. Rajpert-De Meyts, E. Carlsen, R. McLachlan, A. Juul, N. Jørgensen, Decrease in semen quality and Leydig cell function in infertile men: a longitudinal study, *Hum. Reprod.* 33 (11) (2018) 1963–1974.
- [161] U. Handa, T. Sood, R.S. Punia, Testicular Leydig cell tumor diagnosed on fine needle aspiration, *Diagn. Cytopathol.* 38 (9) (2010) 682–684.
- [162] R.I. McLachlan, E. Rajpert-De Meyts, C.E. Hoesli-Hansen, D.M. de Kretser, N.E. Skakkebaek, Histological evaluation of the human testis—approaches to optimizing the clinical value of the assessment: mini Review, *Hum. Reprod.* 22 (10) (2007) 2–16.
- [163] A.H. Payne, M.P. Hardy, *The Leydig Cell in Health and Disease*, Humana Press, Totowa, NJ, 2007.
- [164] D. Augusto, E. Letourte, A. De La Taille, B. Gosselin, X. Leroy Calretin, A valuable marker of normal and neoplastic Leydig cells of the testis, *Appl. Immunohistochem. Mol. Morphol.* 10 (2) (2002) 159–162.
- [165] L. Dong, H. Wang, Z. Su, S. Niu, R. Wang, L. Wu, G. Chen, Steroidogenic acute regulatory protein is a useful marker for Leydig cells and sex-cord stromal tumors, *Appl. Immunohistochem. Mol. Morphol.* 19 (3) (2011) 226–232.
- [166] T.M. Ulbright, Germ cell tumors of the gonads: a selective review emphasizing problems in differential diagnosis, newly appreciated, and controversial issues, *Mod. Pathol.* 18 (Suppl 2) (2005) S61–79.
- [167] S.J. Winters, J.P. Moore jr., B.J. Clark, Leydig cell insufficiency in hypospermatogenesis: a paracrine effect of activin-inhibin signaling? *Andrology* 6 (2) (2018) 262–271.
- [168] M.C. Beattie, L. Adekola, V. Papadopoulos, H. Chen, B.R. Zirkin, Leydig cell aging and hypogonadism, *Exp. Gerontol.* 68 (2015) 87–91.
- [169] J.D. Veldhuis, N.J. Veldhuis, D.M. Keenan, A. Iranmanesh, Age diminishes the testicular steroidogenic response to repeated intravenous pulses of recombinant human LH during acute GnRH-receptor blockade in healthy men, *Am. J. Physiol. Endocrinol. Metab.* 288 (4) (2005) E775–E781.
- [170] M. Dakouane, L. Bicchieray, M. Bergère, M. Albert, F. Vialard, J.A. Selva, Histomorphometric and cytogenetic study of testis from men 29-102 years old, *Fertil. Steril.* 83 (4) (2005) 923–928.
- [171] F.P. Prince, Mitochondrial cristae diversity in human Leydig cells: a revisited look at cristae morphology in these steroid-producing cells, *Anat. Rec.* 254 (1999) 534–541.
- [172] H. Yang, T. Chryssikos, M. Houseni, S. Alzeair, M. Sansovini, S. Irvuri, A. Alavi, The effects of aging on testicular volume and glucose metabolism: an investigation with ultrasonography and FDG-PET, *Mol. Imag. Biol.* 13 (2) (2011) 391–398.
- [173] E. Gorowska-Wojtowicz, M. Duliban, M. Kudrycka, P. Pawlicki, A. Milon, M. Zarzycka, W. Placha, M. Kotula-Balak, A. Ptak, J.K. Wolski, B. Bilinska, Leydig cell tumorigenesis - implication of G-protein coupled membrane estrogen receptor, peroxisome proliferator-activated receptor and xenoestrogen exposure. In vivo and in vitro appraisal, *Tissue Cell* 61 (2019) 51–60.
- [174] M.S. Davidoff, W. Schulze, R. Middendorff, A.F. Holstein, The Leydig cell of the human testis—a new member of the diffuse neuroendocrine system, *Cell Tissue Res.* 271 (3) (1993) 429–439 1993 Mar.
- [175] M. Nistal, R. Paniagua, P. González-Peramato, *Nonneoplastic diseases of the testis*, fourth ed., *Urologic Surgical Pathology*, vol. 12, 2020, pp. 549–730.
- [176] S.J. Lee, S.H. Lee, N.C. Ha, B.J. Park, Estrogen prevents senescence through induction of WRN, Werner syndrome protein, *Horm Res Paediatrics* 74 (1) (2010) 33–40.
- [177] A.J. Pomajzl, L.E. Siref, *Cancer, Leydig cell*, StatPearls [Internet], Treasure Island (FL): S. Pearls Publishing, 2019, <https://www.ncbi.nlm.nih.gov/books/NBK549800/>.
- [178] M.A. Kirschner, J.A. Wider, G.T. Ross, Leydig cell function in men with gonadotrophin-producing testicular tumors, *J. Clin. Endocrinol. Metab.* 30 (4) (1970) 504–511.
- [179] I. Kosmehl, F. Kiss, L. Langbein L, [Stromal tumor of the testis with Leydig cell components. Light and electron microscopy analysis and fluorescence microscopy demonstration of F-actin], *Zentralbl Allg Pathol* 133 (6) (1987) 557–564 ([Article in German]).
- [180] F. Reinke, Contributions to the human histology, *Arch mikr Anat* 47 (1896) 34–41 ([in German]).
- [181] T. Nagano, I. Otsuki, Reinvestigation of the fine structure of Reinke's crystal in the human testicular interstitial cell, *J. Cell Biol.* 51 (1) (1971) 148–161.
- [182] A.R. Sohval, J.L. Gabilove, J. Churg, Ultrastructure of Leydig cell paracrystalline inclusions, possibly related to Reinke crystals, in the normal human testis, *Z. Zellforsch. Mikrosk. Anat.* 142 (1) (1973) 13–26.
- [183] H. Mori, R. Fukunishi, M. Fujii, K. Hataji, T. Shiraishi, K. Matsumoto, Stereological analysis of Reinke's crystals in human Leydig cells, *Virchows Arch. A Pathol. Anat. Histol.* 380 (1) (1978) 1–9.
- [184] M. Jain, H.M. Aiyyer, P. Bajaj, S. Dhar, Intracytoplasmic and intranuclear Reinke's crystals in a testicular Leydig-cell tumor diagnosed by fine-needle aspiration cytology: a case report with review of the literature, *Diagn. Cytopathol.* 25 (3) (2001) 162–164.
- [185] T. Abe, N. Takaha, A. Tsujimura, N. Nonomura, K. Matsumiya, A. Okuyama, K. Miyazaki, Y. Tsujimoto, H. Takayama, K. Aozasa, [Leydig cell tumor of the testis presenting male infertility: a case report], *Hinyokika Kiyo* 49 (1) (2003) 39–42 ([in Japanese]).
- [186] K.P. Hribar, N.E. Warner, A.E. Sherrod, Cytologic identification of Reinke crystalloids in scrapings and imprints of fresh testicular tumors: a simple and rapid technique for intraoperative use, *Arch Pathol Lab Med* 129 (2005) e65–e66.
- [187] N. Nakamura, F. Yasuzumi, Staining of the Reinke crystalloids in the human testis—re-evaluation study, *Okajimas Folia Anat. Jpn.* 82 (3) (2005) 103–110.
- [188] Sh.G. Chovelidze, D.K. Kochiashvili, G.G. Gogeshvili, T. Getta, A. Lababidi, Cases of Leydig cell tumor in male infertility [Article in Russian], *Georgian Med. News* 143 (2007) 76–79.
- [189] Y. Shiraishi, H. Nishiyama, K. Okubo, R. Iguchi, T. Inoue, Y. Watanabe, T. Kamba, K. Yoshimura, A. Kanematsu, T. Nakayama, H. Hatayama, O. Ogawa, [Testicular Leydig Cell Tumor Presenting as Male Infertility: a Case Report], [Article in Japanese] *Hinyokika Kiyo*, 55 (2009), pp. 777–781 12.
- [190] U. Handa, T. Sood, R.S. Punia, Testicular Leydig cell tumor diagnosed on fine needle aspiration, *Diagn. Cytopathol.* 38 (9) (2010) 682–684.
- [191] F.J. Longo, S.A. Coleman, J.R. Givens, Ultrastructural analysis of the testes in male pseudohermaphroditism reductase, *Am. J. Clin. Pathol.* 64 (2) (1975) 145–154.
- [192] A.C. Magalhaes, A new crystal-containing cell in human adrenal cortex, *J. Cell Biol.* 55 (1972) 126–133.
- [193] E. Allara, P.T. Scarpell, G. Scapicchi, [Research on the Ultrastructure of the Interstitial Cells of the Human Testis, with Special Reference to the Genesis of Reinke's Crystals], [Article in Italian] *Boll Soc Ital Biol Sper*, 50 (1974), pp. 1–2 1–2.
- [194] G. Tedde, K. Ostrowski, M. Rozycka, A. Dziedzic-Goclawska, M. Daszkiewicz, A.N. Delrio, A. Montella, Optical diffractometry of the developing or dis-aggregating Reinke crystals in the Leydig cells of the human testis, *Arch. Ital. Anat. Embriol.* 91 (3) (1986) 231–252.
- [195] B. Eyden, S.S. Banerjee, Y. Ru, P.P. Liberski, *The Ultrastructure of Human Tumours Applications in Diagnosis and Research*. Zhejiang University Press, Springer Verlag/Blackwell, Hangzhou China and Heidelberg, 2013 ISBN 978-3-642-39167-5.
- [196] C. Stewart, I. Hammond, Cytologic identification of Reinke crystalloids in ovarian Leydig cell tumor, *Arch. Pathol. Lab Med.* 130 (6) (2006) 765–766.
- [197] T. Nagano, Some observations on the fine structure of the Sertoli cell in the human testis, *Z. für Zellforsch. Mikrosk. Anat.* 73 (1) (1966) 89–106.
- [198] Y. Toyama, Ultrastructural study of crystalloids in Sertoli cells of the normal, intersex and experimental cryptorchid swine, *Cell Tissue Res.* 158 (2) (1975) 205–213.
- [199] N. Livni, Z. Palti, S. Segal, A. Laufer, Fine structure of Sertoli and Leydig cells in azoospermic human testis, *Arch. Pathol. Lab Med.* 101 (8) (1977) 442–445.
- [200] J. Gilloteaux, L.M. Tomasello, D.A. Elgison, Lipid deposits and lipo-mucosomes in human cholecystitis and epithelial metaplasia in chronic cholecystitis, *Ultrastruct. Pathol.* 27 (5) (2003) 313–321.
- [201] J. Gilloteaux, W.S. Hawkins, L.C. Gilloteaux, J. Jasso, T.R. Kelly, Ultrastructural aspects of human cystic duct epithelium as a result of cholelithiasis and cholesterosis, *Microsc. Res. Tech.* 39 (1) (1997) 22–38.
- [202] A.F. Payer, Ultrastructural classification of paracrystalline inclusions in untreated and estrogen treated human Leydig cells, *Anat. Rec.* 198 (2) (1980) 175–182.
- [203] R.P. Kelch, M.R. Jenner, R. Weinstein, S.L. Kaplan, M.M. Grumbach, Estradiol and testosterone secretion by human, simian, and canine testes, in males with hypogonadism and in male pseudohermaphrodites with the feminizing testes syndrome, *J. Clin. Invest.* 51 (4) (1972) 824–830.
- [204] M. Nistal, R. Paniagua, Ultrastructure of testicular biopsy from an XX male, *Virchows Arch. B Cell Pathol. Incl. Mol. Pathol.* 31 (1) (1979) 45–55.

- [205] S. Amati, E. Petrini, E. Ceresi, G. Muzzonigro, M. Polito, Particular ultrastructural aspects of cryptorchid testis in adult and advanced age, *Boll. Soc. Ital. Biol. Sper.* 60 (4) (1984) 805–810.
- [206] E. Sertoli, Dell'esistenza di particolari cellule ramificate nei canalicoli seminiferi del testicolo umano, *Morgagni* 7 (1865) 1–40.
- [207] E. Sertoli, The structure of seminiferous tubules and the development of [spermatids] in rats, *Biol. Reprod.* 99 (3) (2018) 482–503 2018.
- [208] R.E. Mancini, R. Narbaitz, J.C. Lavieri, Origin and development of the germinative epithelium and Sertoli cells in the human testis: cytological, cytochemical, and quantitative study, *Anat. Rec.* 136 (4) (1960) 477–489.
- [209] M. Nistal, R. Paniagua, The postnatal development of the human Sertoli cells, *Z. Mikrosk.-Anat. Forsch. (Leipz.)* 97 (5) (1983) 739–752.
- [210] L.D. Russell, M.D. Griswold, *The Sertoli Cell*, Cache River Press, Clearwater, 1993.
- [211] R. Hess, L.R. França, History of the Sertoli cell discovery, in: M. Griswold, M. Skinner (Eds.), *Sertoli Cell Biology*, Academic Press, New York, 2005.
- [212] F. Nihl, M.L.M. Gomes, F.A.R. Carvalho, A.B. Reis, R. Martell, R.C.N. Melo, F.R.C.L. Almeida, H. Chiarini-Garcia, Revisiting the human seminiferous epithelium cycle, *Hum. Reprod.* 32 (6) (2017) 1170–1182.
- [213] H.J. Grier, M.C. Uribe, F.L. Lo Nostro, S.D. Mims, L.R. Parenti, Conserved form and function of the germinal epithelium through 500 million years of vertebrate evolution, *J. Morphol.* 277 (8) (2016) 1014–1044.
- [214] M.S. Rissley, M. Morse-Gaudio, Comparative aspects of spermatogenic cell metabolism and Sertoli cell function in *Xenopus laevis* and mammals, *J. Exp. Zool.* 261 (2) (1992) 185–193.
- [215] L. Johnson, C.S. Petty, W.B. Neaves, Age-related variation in seminiferous tubules in men A stereological evaluation, *J. Androl.* 7 (5) (1986) 316–322.
- [216] L.D. Russell, H.P. Ren, H. Sinha, I. Hikim, W. Schulze, A.P. Sinha Hikim, A comparative study in twelve mammalian species of volume densities, volumes, and numerical densities of selected testis components, emphasizing those related to the Sertoli cell, *Am. J. Anat.* 188 (1) (1990) 21–30.
- [217] E.A. Ahmed, A.D. Barten-van Rijbroek, H.B. Kal, H. Sadri-Ardekan, S.C. Mizrak, A.M. van Pelt, D.G. de Rooij, Proliferative activity in vitro and DNA repair indicate that adult mouse and human Sertoli cells are not terminally differentiated, quiescent cells, *Biol. Reprod.* 80 (6) (2009) 1084–1091.
- [218] T. Nagano, F. Suzuki, Freeze-fracture observations on the intercellular junctions of Sertoli cells and of Leydig cells in the human testis *Cell Tissue, Res.* 166 (1) (1976) 37–48.
- [219] G. Aumüller, C. Schulze, C. Viebahn, Intermediate filaments in Sertoli cells, *Microsc. Res. Tech.* 20 (1) (1992) 50–72.
- [220] B. Jégou, The Sertoli-germ cell communication network in mammals, *Int. Rev. Cytol.* 147 (1993) 25–96.
- [221] S. Levy, V. Serre, L. Hermo, B. Robaire, The effects of aging on the seminiferous epithelium and the blood-testis barrier of the brown Norway rat, *Andrologia* 20 (3) (1999) 356–365.
- [222] H.H. Yan, D.D. Mruk, E.W. Wong, W.M. Lee, C.Y. Cheng, An autocrine axis in the testis that coordinates spermiogenesis and blood-testis barrier restructuring during spermatogenesis, *Proc. Natl. Acad. Sci. U. S. A.* 105 (26) (2008) 8950–8955.
- [223] A.W. Vogl, K.S. Vaid, J.A. Guttman, The Sertoli cell cytoskeleton, *Adv. Exp. Med. Biol.* 636 (2008) 186–211.
- [224] H.H. Yan, D.D. Mruk, W.M. Lee Wm, C.Y. Cheng, Cross-talk between tight and anchoring junctions-lesson from the testis, *Adv. Exp. Med. Biol.* 636 (2008) 234–254.
- [225] A. Fink, R. Weigel, L. Fink, J. Wilhelm, S. Kliesch, M. Zeiler, M. Bergmann, R. Brehm, Claudin-11 is over-expressed and dislocated from the blood-testis barrier in Sertoli cells associated with testicular intraepithelial neoplasia in men, *Histochem. Cell Biol.* 131 (6) (2009) 755–764.
- [226] C.M. Morrow, D. Mruk, C.Y. Cheng, R.A. Hess, Claudin and occludin expression and function in the seminiferous epithelium, *Phil. Trans. Roy. Soc. Lond. B Biol. Sci.* 365 (1546) (2010) 1679–1696, <https://doi.org/10.1098/rstb.2010.0025>.
- [227] D.D. Mruk, Emergent roles for intercellular adhesion molecule-1 in the restructuring of the blood-testis barrier during spermatogenesis in the mammal, *Histol. Histopathol.* 31 (2) (2016) 59–66.
- [228] A. Stammeler, B.U. Lüftner, S. Kliesch, W. Weidner, M. Bergmann, R. Middendorff, L. Konrad, Highly conserved testicular localization of claudin-11 in normal and impaired spermatogenesis, *PLoS One* 11 (8) (2016) e0160349, <https://doi.org/10.1371/journal.pone.0160349>.
- [229] J. Hollenbach, K. Jung, J. Noelke, H. Gasse, C. Pfarrer, M. Koy, R. Brehm, Loss of connexin43 in murine Sertoli cells and its effect on blood-testis barrier formation and dynamics, *e0198100, PLoS One* 13 (6) (2018) 1–23 10.1371/journal.pone.0198100.eCollection 2018.
- [230] L.R. França, S.A. Auharek, R.A. Hess, J.M. Dufour, B.T. Hinton, Blood-tissue barriers: morphofunctional and immunological aspects of the blood-testis and blood-epididymal barriers, *Adv. Exp. Med. Biol.* 763 (2012) 237–259.
- [231] K.J. Johnson, Testicular histopathology associated with disruption of the Sertoli cell cytoskeleton, *Spermatogenesis* 4 (2) (2015) e979106 eCollection 2014.
- [232] D.D. Mruk, C.Y. Cheng, The mammalian blood-testis barrier: its biology and regulation, *Endocr. Rev.* 36 (5) (2015) 564–591.
- [233] P.G. Stanton, Regulation of the blood-testis barrier, *Semin. Cell Dev. Biol.* 59 (2016) 166–173.
- [234] K. Chojnacka, B. Bilinska, D.D. Mruk, Annexin A2 is critical for blood-testis barrier integrity and spermatid disengagement in the mammalian testis, *Biochim. Biophys. Acta Mol. Cell Res.* 1864 (3) (2017) 527–545.
- [235] B. Yao, L. Zhao, R. Tian, P. Li, Z. Zhu, Y. Xue, H. Chen, Y. Gong, N. Liu, C. Yang, H. Zuping, Z. Li, Seminiferous tubule molecular imaging for evaluation of male fertility: seeing is believing, *Tissue Cell* 58 (2019) 24–32.
- [236] G. Aumüller, S. Peter, Immunohistochemical and ultrastructural study of Sertoli cells in androgen insensitivity, *Int. J. Androl.* 9 (2) (1986) 99–108.
- [237] K. Chui, A. Trivedi, C. Yan Cheng, D.B. Cherbavaz, P.F. Dazin, A.L. Thu Huynh, J.B. Mitchell, G.A. Rabinovich, L.J. Noble-Haesslein, C.M. John, Characterization and functionality of proliferative human Sertoli cells, *Cell Transplant.* 20 (2011) 619–635.
- [238] F. Aslani, T. Sebastian, M. Keidel, S. Fröhlich, H.P. Elsässer, H.C. Schuppe, I. Klug, P. Mahavadi, M. Fijak, M. Bergmann, A. Meinhardt, S. Bhushan, Resistance to apoptosis and autophagy leads to enhanced survival in Sertoli cells, *Mol. Hum. Reprod.* 23 (6) (2017) 370–380.
- [239] M.L.R. França Lr, R.A. Hess, J.M. Dufour, M.C. Hofmann, M.D. Griswold, The Sertoli cell: one hundred fifty years of beauty and plasticity, *Andrology* 4 (2) (2016) 189–212.
- [240] F. Rijo-Ferreira, J.S. Takahashi, Genomics of circadian rhythms in health and disease, *Genome Med.* 11 (1) (2019 Dec 17) 82, <https://doi.org/10.1186/s13073-019-0704-0>.
- [241] Sen H.M. Hoffmann, Role of core circadian clock genes in hormone release and target tissue sensitivity in the reproductive axis, *Mol. Cell. Endocrinol.* 501 (Nov 19) (2019) 110655, <https://doi.org/10.1016/j.mce.2019.110655> ([Epub ahead of print]).
- [242] M.T. Sellix, M.L. Menaker, Circadian clocks in mammalian reproductive physiology: effects of the "other" biological clock on fertility, *Discov. Med.* 11 (59) (2011) 273–281.
- [243] K. Chojnacka, D.D. Mruk, The Src non-receptor tyrosine kinase paradigm: new insights into mammalian Sertoli cell biology, *Mol. Cell. Endocrinol.* 415 (2015) 133–142.
- [244] N.M. Pollak, M. Hoffman, I.J. Goldberg, K. Drosatos, Krüppel-like factors: crippling and un-crippling metabolic pathways, *JACC Basic Transl Sci* 3 (1) (2018) 132–156, <https://doi.org/10.1016/j.jacbt.2017.09.001>.
- [245] X.X. Wang, Y. Zhang, X.Y. Li, J.T.X. Li J, Tang, Y.Y. Li, S.L. Deng, C.Y. Cheng, Y.X. Liu, Kruppel-like factor 6 regulates Sertoli cell blood-testis barrier, *Front. Biosci.* 24 (2019) 1316–1329.
- [246] P. Mao, L. Li, M. Yan, C.K.C. Wong, B. Silvestrini, C. Li, R. Ge, Q. Lian, C.Y. Cheng, F5-peptide and mTORC1/rpS6 effectively enhance BTB transport function in the testis - lesson from the adjuvant model, *Endocrinology* 160 (8A) (2019) 1832–1853.
- [247] S.C. Hewitt, J.C. Harrell, K.S. Korach, Lessons in estrogen biology from knockout and transgenic animals, *Annu. Rev. Physiol.* 67 (2005) 285–308.
- [248] H. Taylor, F. Al-Azzawi, Immunolocalisation of oestrogen receptor beta in human tissues, *J. Mol. Endocrinol.* 24 (2000) 145–155.
- [249] X. Li, H. Li, L. Jia, X. Li, N. Rahman, Oestrogen action and male fertility: experimental and clinical findings, *Cell Mol Life Sci* 72 (20) (2015) 3915–3930.
- [250] [a] J. Choudhuri, M. Aleem, V. Padwal, P. Das Gupta, R.D. Souza, S. Pathak, N. Balasinar, M.K. Gill-Sharma, Effect of estradiol on expression of cytoskeletal proteins during spermatogenesis in testis of sexually mature rats, *Indian J Exp Biol* 43 (11) (2005) 1068–1079; [b] A.R. Means, J.R. Dedman, J.S. Tash, D.J. Tindall, M. van Sickle, M.J. Welsh, Regulation of the testis Sertoli cell by follicle stimulating hormone, *Ann Rev Physiol* 42 (1980) 59–70.
- [251] D.M. de Kretser, J.B. Kerr, C.A. Paulsen, Evaluation of the ultrastructural changes in the human Sertoli cell in testicular disorders and the relationship of the changes to the levels of serum FSH, *Int. J. Androl.* 4 (2) (1981) 129–144.
- [252] B. Boulogne, R. Habert, C. Levacher, Regulation of the proliferation of cocultured gonocytes and Sertoli cells by retinoids, triiodothyronine, and intracellular signaling factors: differences between fetal and neonatal cells, *Mol. Reprod. Dev.* 65 (2003) 194–203.
- [253] V. Rouiller-Fabre, L. Lecerf, C. Gautier, J.M. Saez, R. Habert, Expression and effect of insulin-like growth factor I on rat fetal Leydig cell function and differentiation, *Endocrinology* 139 (1998) 2926–2934.
- [254] D.F. Cameron, F.T. Murray, D.D. Drylie, Ultrastructural lesions in testes from hyperprolactinemic men, *J. Androl.* 5 (4) (1984) 283–293.
- [255] N. Josso, J.Y. Picard, Anti-müllerian hormone, *Physiol. Rev.* 66 (4) (1986) 1038–1090.
- [256] L. Rouiller-Fabre, S. Carmona, R. Abou-Merhi, R. Cate, R. Habert, B. Vigier, Effect of anti-Müllerian hormone (AMH) on Sertoli and Leydig cell functions in fetal and immature rats, *Endocrinology* 139 (1998) 1213–1220.
- [257] R. Olaso, C. Gautier, C. Levacher, J.M. Saez, R. Habert, The immunohistochemical localization of transforming growth factor- $\beta$ 2 in the fetal and neonatal rat testis, *Mol. Cell. Endocrinol.* 126 (1997) 165–172.
- [258] G. Livera, V. Rouiller-Fabre, C. Pairault, C. Levacher, R. Habert, Regulation and perturbation of testicular functions by vitamin A, *Reproduction* 124 (2) (2002) 173–180.
- [259] V. Syriou, D. Papanikolaou, A. Kozyraki, D.G. Goulis, Cytokines and male infertility, *Eur. Cytokine Netw.* 29 (3) (2018) 73–82.
- [260] B. Boulogne, P. Durand, R. Habert, Retinoic acid receptors and retinoid X receptors in the rat testis during fetal and postnatal development: immunolocalization and implication in the control of the number of gonocytes, *Biol. Reprod.* 61 (1999) 1548–1557.
- [261] W. Xia, D.D. Mruk, C.Y. Cheng, C-type natriuretic peptide regulates blood-testis barrier dynamics in adult rat testes, *Proc. Natl. Acad. Sci. U. S. A.* 104 (10) (2007) 3841–3846.
- [262] S.J. Winters, Inhibin is released together with testosterone by the human testis, *J. Clin. Endocrinol. Metab.* 70 (2) (1990) 548–550.
- [263] A. Bergh, S. Cajander, Immunohistochemical localization of inhibin-a in the testes of normal men and in men with testicular disorders, *Int. J. Androl.* 13 (1990) 463–469.
- [264] T.V. Hansson, S.C. Weddington, O. Naess, A. Attramadala, F.S. French, N. Kotite, S.N. Nayfeh, Testicular androgen binding protein (ABP) - a parameter of Sertoli

- cell secretory function, *Curr. Top. Mol. Endocrinol.* 2 (1975) 323–336.
- [265] M.K. Skinner, S.M. Schlitz, C.T. Anthony, Regulation of Sertoli cell differentiated function: testicular transferrin and androgen-binding protein expression, *Endocrinology* 124 (6) (1989) 3015–3024.
- [266] S.H. Hall, M. Conti, F.S. French, D.R. Joseph, Follicle-stimulating hormone regulation of androgen-binding protein messenger RNA in Sertoli cell cultures, *Mol. Endocrinol.* 4 (2) (1990) 349–355.
- [267] V. Santemma, P. Rosati, C. Guerzoni, S. Mariani, F. Beligotti, M. Magnanti, G. Garufi, T. Galoni, A. Fabrini, Human Sertoli cells in vitro: morphological features and androgen-binding protein secretion, *J. Steroid Biochem. Mol. Biol.* 43 (5) (1992) 423–429.
- [268] L. Konrad, M.A. Weber, S. Groos, M. Albrecht, G. Aumüller, Paracrine interaction in testicular somatic cells, *Ital. J. Anat Embryol.* 103 (4 Suppl 1) (1998) 139–152 1998.
- [269] C. Mallidis, H.W. Baker, Fine needle tissue aspiration biopsy of the testis, *Fertil. Steril.* 61 (1994) 367–375.
- [270] T. Al Jishi, C. Sergi, Current perspective of diethylstilbestrol (DES) exposure in mothers and offspring, *Reprod. Toxicol.* 71 (2017) 71–77.
- [271] E. Rosemberg, C.M. Paulsen, The human testis: proceedings of the workshop conference, Positano. *Adv Exp Med Biol.* 10 (1970).
- [272] Q. Wen, E.I. Tan, X. Xiao, Y. Gao, D.S. Chu, D.D. Mruk, B. Silvestrini, C.Y. Cheng, Transport of germ cells across the seminiferous epithelium during spermatogenesis—the involvement of both actin- and microtubule-based cytoskeletons, *Tissue Barriers* 4 (4) (2016) e1265042, <https://doi.org/10.1080/21688370.2016.1265042.eCollection>.
- [273] L. O'Donnell, P.K. Nicholls, M.K. O'Bryan, R.I. McLachlan, P.G. Stanton Spermiation, The process of sperm release, *Spermatogenesis* 1 (1) (2011) 14–35.
- [274] C. Pleuger, D. Fietz, K. Hartmann, H.C. Schuppe, W. Weidner, S. Kliesch, M. Baker, M.K. O'Bryan, M. Bergmann, Expression of ciliated bronchial epithelium 1 during human genitalorgane, Von Möllendorfn Spermatogenesis. *Fertil. Steril.* 108 2017, pp. 47–54 1.
- [275] Y. Morita, Histological investigation of testis in infertile man. Part II. Pathological problems, *Nagoya J. Med. Sci.* 34 (1971) 113–129.
- [276] D. Well, H. Yang, M. Houseni, S. Iruvuri, S. Alzeair, M. Sansovini, N. Wintering, A. Alavi, D.A. Torigian, Age-related structural and metabolic changes in the pelvic reproductive end organs, *Semin. Nucl. Med.* 37 (3) (2007) 173–184.
- [277] T. Al-Hussain, Tubular sclerosis/interstitial fibrosis only, *PathologyOutlines.com website*, 2019. <https://www.pathologyoutlines.com/topic/testistubularsclerosis.html>.
- [278] H. Stieve, Männliche Genitalorgane, ed. W. von Möllendorf (Ed.), *Handbuch der Mikroskopischen Anatomie des Menschen*, vol. 7, Springer Verlag, Berlin, 1930, pp. 1–399 2.
- [279] S.R. Bawa, Fine structure of the Sertoli cell of the human testis, *J Ultrastruct. Res.* 9 (1963) 459–474.
- [280] T. Nagano, Some observation on the fine structure of the Sertoli cell in the human testis, *Z. Zellforsch.* 73 (1966) 89–106.
- [281] A.R. Sohval, Y. Suzuki, J.L. Gabrielove, J. Churg, Ultrastructure of crystalloids in spermatogonia and Sertoli cells of normal human testis, *J. Ultrastruct. Res.* 34 (1971) 83–102.
- [282] Y. Toyama, Ultrastructural study of crystalloids in Sertoli cells of the normal, intersex and experimental cryptorchid swine, *Cell Tissue Res.* 158 (1975) 205–213.
- [283] Y. Nakazato, A. Ogawa, M. Kawarai, Histochemical and electron microscopic studies of Charcot-Böttcher crystalloids in human Sertoli cells, *Kitakanto Med. J.* 32 (6) (1982) 547–552.
- [284] M. Kaya, R. Türkyilmaz, An ultrastructural study on the presence of various types of crystals in the infertile human testis, *Anat. Embryol.* 172 (2) (1985) 217–225.
- [285] I. Takeda, Y. Ohtsuki, K. Fujita, T. Akagi, A case of stromal tumor of the testis with peculiar crystalloid structures, *Gan No Rinsho* 31 (1) (1985) 102–106 ([Article in Japanese]).
- [286] N. Livni, Z. Palti, S. Segal, A. Laufer, Fine structure of Sertoli and Leydig cells in azoospermic human testis, *Arch. Pathol. Lab Med.* 101 (8) (1977) 442–445.
- [287] B. Tetu, J.Y. Ro, A.G. Ayala, Large cell calcifying Sertoli cell tumor of the testis. A clinicopathologic, immunohistochemical, and ultrastructural study of two cases, *Am. J. Clin. Pathol.* 96 (6) (1991) 717–722.
- [288] Y. Monobe, T. Manabe, Malignant sex-cord stromal tumor of the testis: report of a case with special reference to its unusual intracytoplasmic substructures, *Jpn. J. Clin. Oncol.* 22 (6) (1992) 414–420.
- [289] A. Amin, A. Monabati, A. Tadayon, S.Y. Attaran, P.V. Kumar, Testicular fine needle aspiration cytology in male infertility, *Acta Cytol.* 50 (2) (2006) 147–150.
- [290] A. Terquem, J.-P. Dadoune, Morphological findings in varicocele. An ultrastructural study of 30 bilateral testicular biopsies, *Int. J. Androl.* 4 (1981) 515.
- [291] F.N. Ghadially, *Ultrastructural Pathology of the Cell and Matrix*, fourth ed., Butterworth-Heinemann, Boston, 1997, p. 97 1040.
- [292] M. Oishi, M. Takahashi, H. Amasaki, T. Janssen, S.D. Johnston, The seminiferous epithelial cycle and microanatomy of the koala (*Phascolarctos cinereus*) and southern hairy-nosed wombat (*Lasiornhinus latifrons*) testis, *J. Anat.* 222 (3) (2013) 380–389.
- [293] G. Kaur, L.A. Thompson, J.M. Dufour, Sertoli cells—immunological sentinels of spermatogenesis, *Semin. Cell Dev. Biol.* 30 (2014) 36–44.
- [294] Y. Clermont, Renewal of spermatogonia in man, *Am. J. Anat.* 118 (2) (1966) 509–524.
- [295] Y. Clermont, Spermatogenesis in man. A study of the spermatogonial population, *Fertil. Steril.* 17 (1966) 705–721.
- [296] J. André, *The Sperm Cell. Fertilizing Power, Surface Properties, Motility, Nucleus and Acrosome, Evolutionary Aspects*, Martinus Nijhoff Publishers, Den Hague – The Netherland, 1983.
- [297] R. Paniagua, M. Nistal, P. Amat, M.C. Rodríguez, Ultrastructural observations on nuclei and related structures during human spermatogenesis, *Anat. Embryol.* 174 (3) (1986) 301–306.
- [298] J. Gravis, Interrelationships between Sertoli cells and germ cells in the Syrian hamster, *Z. Mikrosk.-Anat. Forsch. (Leipz.)* 93 (2) (1979) 321–342.
- [299] D.G. De Rooij, L.D. Russell, All you wanted to know about spermatogonia but were afraid to ask, *J. Androl.* 21 (6) (2000) 776–798.
- [300] R.A. Hess, R. de Franca, Spermatogenesis and cycle of the seminiferous epithelium, in: C. Yan Cheng (Ed.), *Molecular Mechanisms in Spermatogenesis*, vol. 636, *Adv Expl Med Biol*, 2008, pp. 1–15.
- [301] P.T. Saunders, M.R. Millar, S. Macpherson, D.S. Irvine, N.P. Groome, L.R. Evans, R.M. Sharpe, G.A. Scobie, ERbeta1 and the ERbeta2 splice variant (ERbeta2/beta2) are expressed in distinct cell populations in the adult human testis, *J. Clin. Endocrinol. Metab.* 87 (2002) 2706–2715.
- [302] S. Ogawa, S. Inoue, T. Watanabe, H. Hiroi, A. Orimo, T. Hosoi, Y. Ouchi, M. Muramatsu, The complete primary structure of human estrogen receptor beta (hERβ) and its heterodimerization with ER in vivo and in vitro, *Biochem. Biophys. Res. Commun.* 243 (1998) 122–126.
- [303] E. Enmark, M. Peltö-Huikko, K. Grandien, S. Lagercrantz, J. Lagercrantz, G. Fried, M. Nordenskjöld, J.A. Gustafsson, Human estrogen receptor β-gene structure, chromosomal localization, and expression pattern, *J. Clin. Endocrinol. Metab.* 82 (1997) 4258–4265.
- [304] C. Guido, I. Perrotta, S. Panza, E. Middea, P. Avena, M. Santoro, S. Marsico, P. Imbrogno, S. Andò, S. Aquila, Human sperm physiology: estrogen receptor alpha (ERα) and estrogen receptor beta (ERβ) influence sperm metabolism and may be involved in the pathophysiology of varicocele-associated male infertility, *J. Cell. Physiol.* 226 (12) (2011) 3403–3412.
- [305] S. Solakidi, A.-M.G. Psarra, S. Nikolopoulos, C.E. Sekeris, Estrogen receptors α and β (ERα and ERβ) and androgen receptor (AR) in human sperm: localization of ERβ and AR in mitochondria of the midpiece, *Hum. Reprod.* 20 (12) (2005) 3481–3487.
- [306] V. Pentikainen, K. Erkkilä, L. Suomalainen, M. Parvinen, L. Dunkel, Estradiol acts as a germ cell survival factor in the human testis in vitro, *J. Clin. Endocrinol. Metab.* 85 (2000) 2057–2067.
- [307] B. Boulogne, R. Olaso, C. Levacher, P. Durand, R. Habert, Apoptosis and mitosis in gonocytes of the rat testis during foetal and neonatal development, *Int. J. Androl.* 22 (1999) 356–365.
- [308] M.L. Escobar, O.M. Echeverría, Y.M. Valenzuela, R. Ortiz, N. Torres-Ramírez, G.H. Vázquez-Nin, Histochemical study of the emergence of apoptosis and altered SYCP3 protein distribution during the first spermatogenic wave in Wistar rats, *Anat. Rec.* 302 (11) (2019) 2082–2092.
- [309] J.E.M. Dunleavy, M. O'Bryan, P.G. Stanton, L. O'Donnell, The cytoskeleton in spermatogenesis, *Reproduction*. pii: For. Rep. 18–0457 (2018) R1.
- [310] A. Kumar, S. Raut, N.H. Balasnor, Endocrine regulation of sperm release, *Reprod. Fertil. Dev.* 30 (12) (2018) 1595–1603.
- [311] M. Lucini, F. Francavilla, I. Porazz, B. Macerola, G. Forti, E. Baldi, Human spermatozoa as a model for studying membrane receptors mediating rapid non-genomic effects of progesterone and estrogens, *Steroids* 69 (8–9) (2004) 553–559.
- [312] S. Aquila, E. Middea, S. Catalano, S. Marsico, M. Lanzino, I. Casaburi, I. Barone, R. Bruno, S. Zupo, S. Andò, Human sperm express a functional androgen receptor: effects on PI3K/AKT pathway, *Hum. Reprod.* 22 (10) (2007) 2594–2605.
- [313] L. Saucedo, G.N. Buffa, M. Rosso, T. Guillardoy, A. Góngora, M.J. Munuce, M.H. Vazquez-Levin, C. Marín-Briggiler, Fibroblast growth factor receptors (FGFRs) in human sperm: expression, functionality and involvement in motility regulation, *PLoS One* 10 (5) (2015 May 13) e0127297, <https://doi.org/10.1371/journal.pone.0127297> eCollection 2015.
- [314] D.J. Garbarino Azúa, L. Saucedo, S. Giordana, M.L. Magri, M.G. Buffone, F. Neuspiller, M.H. Vazquez-Levin, C. Marín-Briggiler, Fibroblast growth factor 2 (FGF2) is present in human spermatozoa and is related with sperm motility. The use of recombinant FGF2 to improve motile sperm recovery, *Andrology* 5 (5) (2017) 990–998.
- [315] M. Dakouane-Giudicelli, M. Bergère, M. Albert, V. Sézancin, C. Rouillac-Le Sciellour, F. Vialard, N. Lédée, O. Cussenot, Y. Giudicelli, J. Selva, [Late paternity: spermatogenic aspects], *Gynecol. Obstet. Fertil.* 34 (9) (2006) 855–859.
- [316] M.H.M. Abdelhamid, C. Esquerre-Lamare, M. Walschaerts, G. Ahmad, R. Miesusset, S. Hamdi, L. Bujan, Experimental mild increase in testicular temperature has drastic, but reversible, effect on sperm aneuploidy in men: a pilot study, *Reprod. Biol.* 19 (2) (2019) 189–194.
- [317] H. Yang, T. Chryssikos, M. Houseni, S. Alzeair, M. Sansovini, S. Iruvuri, D.A. Torigian, H. Zhuang, S. Dadparvar, S. Basu, A. Alavi, The trigger a cascade of events further mediated by a loss of estrogen producing cells in the testes, *Mol. Imag. Biol.* 13 (2) (2011) 391–398.
- [318] P. Dostalova, E. Zatecka, K. Dvorakova-Hortova, Of oestrogens and sperm: a review of the roles of oestrogens and oestrogen receptors in male reproduction, *Int. J. Mol. Sci.* 18 (5) (2017) 904–927, <https://doi.org/10.3390/ijms18050904> PMID: 28441342; PMCID: PMC5454817.
- [319] O. Lubarsch, Ueber das Vorkommen krystallinischer und krystalloider Bildungen in den Zellen des menschlichen Hodens, *Virchows Arch. Pathol. Anat.* 145 (1896) 316–338.
- [320] C.R. Prüll, [Otto Lubarsch (1860-1933) and pathology at the Berlin Charité from 1917 to 1928. From the trauma of war time destruction to the daily routine of a German national university teacher of the Weimar Republic], *Sudhoffs Arch. Z. Wissenschaftsgesch.* 81 (2) (1997) 193–210 ([Article in German]).
- [321] T. Nagano, The crystalloid of Lubarsch in the human spermatogonium, *Z. Zellforsch. Mikrosk. Anat.* 97 (4) (1969) 491–501.

- [322] R. Sohval, Y. Suzuki, J.L. Gabrilove, J. Churg, Ultrastructure of crystalloids in spermatogonia and Sertoli cells of normal human testis, *J Ultrastruct Res* 34 (1971) 83–102.
- [323] F. Neumann, F.A. Diallo Fa, S.H. Hasan, B. Schenck, I. Traore, The influence of pharmaceutical compounds on male fertility, *Andrologia* 8 (3) (1976) 203–235.
- [324] D.M. Kristense, C. Desdoits-Lethimonier, A.L. Mackey, M.D. Dalgaard, F. De Mas, C.H. Munkbøl, B. Styrisshave, J.P. Antignac, B. Le Bizec, C. Platel, A. Hay-Schmidt, T.K. Jensen, L. Lesné, S. Mazaud-Guittot, K. Kristiansen, S. Brunak, M. Kjaer, A. Juul, B. Jégou, Ibuprofen alters human testicular physiology to produce a state of compensated hypogonadism, *Proc. Natl. Acad. Sci. U. S. A.* 115 (4) (2018) E715–E724.
- [325] Erratum: Correction for D.M. Kristensen et al., Ibuprofen alters human testicular physiology to produce a state of compensated hypogonadism, *Proc. Natl. Acad. Sci. U. S. A.* 115 (17) (2018) E41–43.
- [326] B. Jégou, D.M. Kristensen, Clarifying the link between ibuprofen and hypogonadism, *Nat. Rev. Urol.* 16 (3) (2019) 201–201.
- [327] C.Y. Cheng, D.D. Mruk, The blood-testis barrier and its implications for male contraception, *Pharmacol. Rev.* 64 (1) (2012) 16–64.
- [328] R.A. Hess, M. Nakai M, Histopathology of the male reproductive system induced by the fungicide benomyl, *Histol. Histopathol.* 15 (2000) 207–224.
- [329] E.R. Coper, A.R. Jones, H. Jackson, Effects of alpha-chlorohydrin and related compounds on the reproductive organs and fertility of the male rat, *Reproduction* 38 (2) (1974) 379–386 1974.
- [330] I. Virtanen I, M. Kallajoki, O. Närvänen, J. Paranko, L.E. Thornell, M. Miettinen, V.P. Lehto, Peritubular myoid cells of human and rat testis are smooth muscle cells that contain desmin-type intermediate filaments, *Anat. Rec.* 215 (1) (1986) 10–20.
- [331] M. Maekawa, K. Kamimura, T. Nagano, Peritubular myoid cells in the testis: their structure and function, *Arch. Histol. Cytol.* 59 (1) (1996) 1–13.
- [332] L.X. Benton, L.X. Shan, M.P. Hardy, Differentiation of adult Leydig cells, *J. Steroid Biochem. Mol. Biol.* 53 (1995) 61–68.
- [333] H. Chen, R.S. Ge, B.R. Zirkin, Leydig cells: from stem cells to aging, *Mol. Cell. Endocrinol.* 306 (2009) 9–16 2009.
- [334] S.J. Potter, D.L. Kumar, T. DeFalco, Origin and differentiation of androgen-producing cells in the gonads, *Results Probl. Cell Differ.* 58 (2016) 101–134.
- [335] C.A. Pearl, H. Mason, J.F. Roser, Immunolocalization of estrogen receptor alpha, estrogen receptor beta and androgen receptor in the pre-, peri- and post-pubertal stallion testis, *Anim. Reprod. Sci.* 125 (1–4) (2011) 103–111.
- [336] R. Zhou, J. Wu, B. Liu, Y. Jiang, W. Chen, J. Li, Q. He, Z. He, The roles and mechanisms of Leydig cells and myoid cells in regulating spermatogenesis, *Cell. Mol. Life Sci.* 76 (14) (2019) 2681–2695.
- [337] K. Miyake, M. Yamamoto, H. Mitsuya, Pharmacological and histological evidence for adrenergic innervation of the myoid cells in the rat seminiferous tubule, *Tohoku J. Exp. Med.* 149 (1) (1986) 79–87.
- [338] K. Miyake, M. Yamamoto, H. Narita, J. Hashimoto, H. Mitsuya, Evidence for contractility of the human seminiferous tubule confirmed by its response to noradrenaline and acetylcholine, *Fertil. Steril.* 46 (4) (1986) 734–737.
- [339] M. Yamamoto, H. Takaba, J. Hashimoto, K. Miyake, Evidence for innervation of the myoid cell in the human seminiferous tubule, *Urol. Int.* 42 (2) (1987) 137–139.
- [340] F.P. Prince, Ultrastructural evidence of indirect and direct autonomic innervation of human Leydig cells: comparison of neonatal, childhood and pubertal ages, *Cell Tissue Res.* 269 (1992) 383–390.
- [341] T.E. Adrian, J. Gu, J.M. Allen, K. Tatemoto, J.M. Polak, S.R. Bloom, Y. Neuropeptide, The human male genital tract, *Life Sci.* 24 (1984) 2643–2678.
- [342] A. Vaalasti, H. Tainio, M. Peltö-Huikko, A. Hervonen, A light and electron microscope demonstration of VIP- and enkephalin-immunoreactive nerves in the human male genitourinary tract, *Anat. Rec.* 215 (1986) 21–27.
- [343] E. Wespes, S. Schiffmann, J. Gilloteaux, C. Schulman, G. Vierendeels, R. Menu, G. Pelletier, H. Vaudry, J.J. Vanderhaeghen, Study of neuropeptide Y-containing nerve fibers in the human penis, *Cell Tissue Res.* 254 (1) (1988) 69–74.
- [344] H. Tainio, Peptidergic innervation of the human testis and epididymis, *Acta Histochem.* 96 (1994) 415–420.
- [345] J.C. Jørgensen, A. Giwercman, B. Ottesen, Y. Neuropeptide, The human prenatal and mature gonads, *Neuropeptides* 30 (1996) 293–301.
- [346] Y.G. Gong, M.M. Feng, X.N. Hu, Y.Q. Wang, M. Gu, W. Zhang, R.S. Ge, Peptidergic not monoaminergic fibers profusely innervate the young adult human testis, *J. Anat.* 214 (3) (2009) 330–338.
- [347] A. Anouar, A. Schirar, G. Germain, Relaxant effect of the calcitonin gene-related peptide (CGRP) on the nonpregnant and pregnant rat uterus. Comparison with vascular tissue, *Naunyn-Schmiedeberg's Arch. Pharmacol.* 1357 (1998) 446–453 19980.
- [348] S.Y. Yousufzai, A.A. Abdel-Latif, Calcitonin gene-related peptide relaxes rabbit iris dilator smooth muscle via cyclic AMP-dependent mechanisms: cross-talk between the sensory and sympathetic nervous system, *Curr. Eye Res.* 17 (1998) 197–204.
- [349] A. Tripiciano, F. Palombi, E. Ziparo, A. Filippini, Dual control of seminiferous tubule contractility mediated by ETA and ETB endothelin receptor subtypes, *Faseb. J.* 11 (4) (1997) 276–286.
- [350] F. Palombi, A. Filippini, C. Chiarenza, Cell-cell interactions in the local control of seminiferous tubule contractility, *Contraception* 65 (4) (2002) 289–291.
- [351] S. Arrowsmith, S. Wray Oxytocin, Its mechanism of action and receptor signalling in the myometrium, *J. Neuroendocrinol.* 26 (6) (2014) 356–369.
- [352] P.K. Wrzal, E. Goupil, S.A. Laporte, T.E. Hébert, H.H. Zingg, Functional interactions between the oxytocin receptor and the  $\beta_2$ -adrenergic receptor: implications for ERK1/2 activation in human myometrial cells, *Cell. Signal.* 24 (1) (2012) 333–341.
- [353] P.T. Saunders, Germ cell-somatic cell interactions during spermatogenesis, *Reproduction* 61 (2003) 91–101.
- [354] T. Svingen, P. Koopman, Building the mammalian testis: origins, differentiation, and assembly of the component cell populations, *Genes Dev.* 27 (22) (2013) 2409–2426.
- [355] Kühnert E. Nieschlag, Reproductive functions of the ageing male, *Hum. Reprod. Update* 10 (4) (2004) 327–339.
- [356] E.H. Stephen, A. Chandra, Declining estimates of infertility in the United States: 1982–2002, *Fertil. Steril.* 86 (2006) 516–523 2006.
- [357] I.D. Harris, C. Fronczak, L. Roth, R.B. Meacham, Fertility and the aging male, *Rev. Urol.* 13 (4) (2011) e184–e190.
- [358] L. Sibert, E. Lacarrière, A. Safsaf, N. Rives, Fonctions testiculaires du sujet âgé [Aging of the human testis]. [Article in French], *Presse Med.* 43 (2) (2014) 171–177.
- [359] M. Dakouane-Giudicelli, M. Bergère, M. Albert, V. Sérazin, C. Rouillac-Le Scieflour, F. Vialard, N. Lédée, O. Cussenot, Y. Giudicelli, J. Selva, [Late paternity: spermatogenetic aspects], *Gynecol. Obstet. Fertil.* 34 (9) (2006 Sep) 855–859.
- [360] S.M. Harman, P.D. Tsitouras, Reproductive hormones in aging men. I. Measurement of sex steroids, basal luteinizing hormone, and Leydig cell response to human chorionic gonadotropin, *J. Clin. Endocrinol. Metab.* 51 (1) (1980) 35–40.
- [361] S.M. Harman, P.D. Tsitouras, P.T. Costa, M.R. Blackman, Reproductive hormones in aging men. II. Basal pituitary gonadotropins and gonadotropin responses to luteinizing hormone-releasing hormone, *J. Clin. Endocrinol. Metab.* 54 (3) (1982) 547–551.
- [362] M.R. Blackman, P.D. Tsitouras, S.M. Harman, Reproductive hormones in aging men. III: basal and LHRH-stimulated serum concentrations of the common alpha-subunit of the glycoprotein hormones, *J. Gerontol.* 42 (5) (1987) 476–481.
- [363] R. Muniyappa, S.D. Sullivan, S.H. Tella, B.S. Abel, S.M. Harman, M.R. Blackman, Effects of growth hormone administration on luteinizing hormone secretion in healthy older men and women, *Phys. Rep.* 5 (23) (2017) 1–8, <https://doi.org/10.14814/phy2.e13516>.
- [364] J. Handelsman, S. Staraj, Testicular size: the effects of aging, malnutrition, and illness, *J. Androl.* 6 (3) (1985) 144–151.
- [365] D. Well, H. Yang, M. Houseni, S. Iruvuri, S. Alzeair, M. Sansovini, N. Wintering, A. Alavi, D.A. Torrigian, Age-related structural and metabolic changes in the pelvic reproductive end organs, *Semin. Nucl. Med.* 37 (3) (2007) 173–184.
- [366] H. Yang, T. Chryssikos, M. Houseni, S. Alzeair, M. Sansovini, S. Iruvuri, et al., The effects of aging on testicular volume and glucose metabolism: an investigation with ultrasonography and FDG-PET, *Mol. Imag. Biol.* 13 (2) (2011) 391–398.
- [367] J. Aiman, P.F. Brenner, P.C. MacDonald, Androgen and estrogen production in elderly men with gynecomastia and testicular atrophy after mumps orchitis, *J. Clin. Endocrinol. Metab.* 50 (2) (1980) 380–386, <https://doi.org/10.1210/jcem-50-2-380>.
- [368] T.L. Andres, T. Trainer, D.J. Lapenas, Small vessel alterations in the testes of infertile men with varicocele, *Am. J. Clin. Pathol.* 76 (4) (1981) 378–384, <https://doi.org/10.1093/ajcp/76.4.378>.
- [369] G. O'Donovan, A.J. Blazeovich, C. Boreham, A.R. Cooper, H. Crank, U. Ekelund, K.R. Fox, P. Gately, B. Giles-Corti, J.M.R. Gill, M. Hamer, I. McDermott, M. Murphy, N. Mtrie, J.J. Reilly, J.M. Saxton, E. Stamatakis, The ABC of physical activity for health: a consensus statement from the British Association of Sport and Exercise Sciences, *J. Sports Sci.* 2 (6) (2010) 573–591.
- [370] C.R. Jenkin, R.M. Eime, H. Westerbeek, G. O'Sullivan, J.G. van Uffelen, Sport and ageing: a systematic review of the determinants and trends of participation in sport for older adults, *BMC Publ. Health* 17 (1) (2017) 976–996, <https://doi.org/10.1186/s12889-017-4970-8> 20170.
- [371] D.R. Berlowitz, A.J. Rose, Who gets testosterone? Patient characteristics associated with testosterone prescribing in the Veteran Affairs System: a cross-sectional study, *J. Gen. Intern. Med.* 32 (3) (2017) 304–311.
- [372] T.M. Creagh, A. Rubin, D.J. Evans, Hepatic tumours induced by anabolic steroids in an athlete, *J. Clin. Pathol.* 41 (1988) 441–443.
- [373] S. Basaria, Androgen abuse in athletes: detection and consequences, *J. Clin. Endocrinol. Metab.* 85 (4) (2010) 1533–1543.
- [374] R.I. Wood, S.J. Stanton, Testosterone and sport: current perspectives, *Horm. Behav.* 61 (1) (2012) 147–155.
- [375] C. Wittnich, Age-related differences in myocardial metabolism affects response to ischemia. Age in heart tolerance to ischemia, *Am. J. Cardiovasc. Pathol.* 4 (2) (1992) 175–180.
- [376] G.S. Richardson, Circadian rhythms and aging, in: Edward L. Schneider, John W. Rowe (Eds.), *Handbook of the Biology of Aging*, third ed., Academic Press, Inc, San Diego, 1990, pp. 1–275.
- [377] J. Gandhi, R.J. Hernandez, A. Chen, N.L. Smith, Y.R. Sheynkin, G. Joshi, S.A. Khan, Impaired hypothalamic-pituitary-testicular axis activity, spermatogenesis, and sperm function promote infertility in males with lead poisoning, *Zygote* 25 (2) (2017) 103–110.
- [378] A. Ray (Ed.), *Dictionnaire Historique de la Langue Française*, third ed., Paris : Dictionnaires Le Robert, 2000, pp. 2249–2265.
- [379] <https://www.etymonline.com/word/testicle>.
- [380] A.C. McAuliffe, 'Nuts!', as reported to be the answer from American commander Brig. General A. C. McAuliffe to the German general D. G. H. Freiherr von Lüttwitz, Bastogne, Belgium, 22 (1944) December.