

THESIS / THÈSE

MASTER EN BIOCHIMIE ET BIOLOGIE MOLÉCULAIRE ET CELLULAIRE

Est-ce que la Triamcinolone Hexacetonide à une dose de 25 mg administrée pour le traitement de l'ostéoarthrite affecte la structure du cartilage et des ménisques dans le genou: une étude expérimentale dans un modèle ovin ?

Crokaert, Florian

Award date:
2016

Awarding institution:
Universite de Namur

[Link to publication](#)

General rights

Copyright and moral rights for the publications made accessible in the public portal are retained by the authors and/or other copyright owners and it is a condition of accessing publications that users recognise and abide by the legal requirements associated with these rights.

- Users may download and print one copy of any publication from the public portal for the purpose of private study or research.
- You may not further distribute the material or use it for any profit-making activity or commercial gain
- You may freely distribute the URL identifying the publication in the public portal ?

Take down policy

If you believe that this document breaches copyright please contact us providing details, and we will remove access to the work immediately and investigate your claim.

UNIVERSITY OF NAMUR

Faculty of Sciences



Does triamcinolone hexacetonide at 25 mg affect cartilage and menisci structure in the treatment of knee OA: an experimental study in an ovine model?

**Master thesis submitted for obtaining
the academic grade of master 120 in biochemistry, and cellular and molecular biology**

Florian Crokaert

Supervisor: Jean-Michel Vandeweerdt

Integrated veterinary research unit (IVRU)

January 2016

Est-ce que la Triamcinolone Hexacetonide à une dose de 25 mg administrée pour le traitement de l'ostéoarthrite affecte la structure du cartilage et des ménisques dans le genou: une étude expérimentale dans un modèle ovin ?

CROKAERT Florian

Résumé

L'ostéoarthrite du genou est une maladie répandue dans la population humaine. A l'heure actuelle, aucun traitement efficace ne permet de soigner cette maladie. Les injections intra articulaires de corticostéroïdes dans l'articulation du genou sont pratiquées pour leurs effets anti-inflammatoires. L'impact de ces injections sur les structures cartilagineuses du genou reste peu connu. Actuellement, il n'y a pas de preuves en suffisance quant à leurs effets sur les ménisques et le cartilage mais les doses fortes semblent avoir un effet délétère.

Le but de ce mémoire est d'étudier l'effet d'un corticostéroïde, la triamcinolone hexacétonide (TH), à une dose clinique (25 mg) sur le cartilage et les ménisques. Pour cette étude, le modèle ovin a été choisi car l'anatomie de son genou est proche de celle de l'homme. 18 moutons sains ont été enrôlés dans l'étude. Les genoux ont été randomisés et injectés avec une solution saline (groupe contrôle) ou de TH. 4 semaines après injection, les animaux ont été euthanasiés. La structure du cartilage et des ménisques a été étudiée grâce à des méthodes histologiques. Les modifications au sein du ménisque ont également été évaluées grâce à des techniques d'imagerie compositionnelle en résonance magnétique nucléaire (T2 mapping).

Les résultats histologiques pour le cartilage ont montré une baisse dans le contenu de protéoglycans et une diminution dans la densité cellulaire pour le groupe injecté avec le TH. Les résultats histologiques pour les ménisques ont montré une augmentation de la prolifération cellulaire dans le groupe injecté avec le TH. Le T2 mapping n'a pas permis d'observer de différence significative.

Mémoire de master 120 en biochimie et biologie moléculaire et cellulaire

Janvier 2016

Promoteur: J-M Vandeweerd

University of Namur
FACULTY OF SCIENCES
Secrétariat du Département de Biologie
Rue de Bruxelles 61 - 5000 NAMUR
Téléphone: + 32(0)81.72.44.18 - Téléfax: + 32(0)81.72.44.20
E-mail: joelle.jonet@unamur.be - <http://www.unamur.be>

Does triamcinolone hexacetonide at 25 mg affect cartilage and menisci structure in the treatment of knee OA: an experimental study in an ovine model?

CROKAERT Florian

Abstract

Osteoarthritis is a common disease in the human population. Intra-articular injections of corticosteroids, a drug commonly used for the disease, are generally administered to patients for their anti-inflammatory effects. However, the impact on cartilaginous structure in the knee is not known. Actually, there is not enough evidence about the positive or negative impact of CS on cartilage and menisci but high doses seem to have a deleterious effect.

The objective of this study was to assess the effect a corticosteroid, triamcinolone hexacetonide (TH), at a dose generally administered to patients (25 mg) in order to study the impact on cartilage and menisci. The ovine model was used because sheep share similarities with human knee. 18 healthy sheep were enrolled in the study. Right and left knee were randomized and injected with saline solution (control group) or TH. 4 weeks after injections, sheep were euthanized. Structural changes of articular cartilage and menisci in the knee were studied with histological method. The biochemical changes inside the menisci were also evaluated by compositional magnetic resonance imaging (T2 mapping).

The histological results for cartilage showed a decrease in proteoglycan content and chondrocytes density for the group injected with TH. Results for menisci did not show significant difference except for cellular proliferation that increase in menisci of TH group. No significant difference was found with T2 mapping technique.

Master thesis of master 120 in biochemistry, and cellular and molecular biology

January 2016

Supervisor: J-M Vandeweerd

Table content

TABLE CONTENT	5
ABBREVIATION LIST	7
1.1 <i>Osteoarthritis</i>	9
II. RELEVANT BACKGROUND	15
2.1 <i>Histological structure of articular cartilage</i>	15
2.2 <i>Histological structure of meniscal cartilage</i>	19
III. RESEARCH QUESTION	25
IV. MATERIAL AND METHODS	27
4.1 <i>Ethical statement</i>	27
4.2 <i>Experimental animals and selection criteria</i>	27
4.3 <i>Housing and husbandry</i>	27
4.4 <i>Study design, allocating animals to experimental groups and blinding</i>	29
4.5 <i>Experimental procedure</i>	31
4.5.1 <i>Lameness evaluation and gait analysis</i>	31
4.5.2 <i>Anesthesia</i>	31
4.5.3 <i>Injections</i>	31
4.5.4 <i>Euthanasia</i>	31
4.6 <i>Experimental outcomes</i>	33
4.6.1 <i>CTA imaging</i>	33
4.6.2 <i>Magnetic resonance imaging (MRI)</i>	33
4.6.3 <i>Gross anatomy</i>	41
4.6.4 <i>Histology of cartilage</i>	41
4.6.5 <i>Histology of menisci</i>	41
4.6.6 <i>Biochemical assessment</i>	43
4.6.7 <i>Statistical analysis</i>	45
V. RESULTS	47
5.0 <i>Study population</i>	47
5.1 <i>Computed tomography arthrography (CTA)</i>	47
5.2 <i>Histology of cartilage</i>	47
5.3 <i>Histology of menisci</i>	53
5.4 <i>T2 mapping assessment</i>	61
VI. DISCUSSION	67
<i>Study limitations</i>	71
VII. PERSPECTIVES AND CONCLUSIONS	73
VIII. REMERCIEMENTS	77
IX. REFERENCES	79

Abbreviation list

CS: Corticosteroid

CTA: Computed tomography arthrography

GR: Receptor for glucocorticoid

HA: Hyaluronic acid/Hyaluronan

IACS: Intra-articular corticosteroid

IL-1: Interleukin-1

LFC: Lateral femoral condyle

LTC: Lateral tibial condyle

MFC: Medial femoral condyle

ML: Lateral menisci

MM: Medial menisci

MMP: Matrix metalloproteinase

MRI: Magnetic resonance imaging

MTC: Medial tibial condyle

ECM: Extracellular matrix

GAG: Glycosaminoglycan

NO: Nitric oxide

OA: Osteoarthritis

OARSI: Osteoarthritis research society international

OH-Pro: Hydroxyproline

PG: Proteoglycan

PGE2: Prostaglandin E2

PK/PD:
Pharmacokinetic/Pharmacodynamic

ROI: Region of interest

TA: Triamcinolone acetonide

TH: Triamcinolone hexacetonide

TNF- α : Tumor necrosis factor-alpha

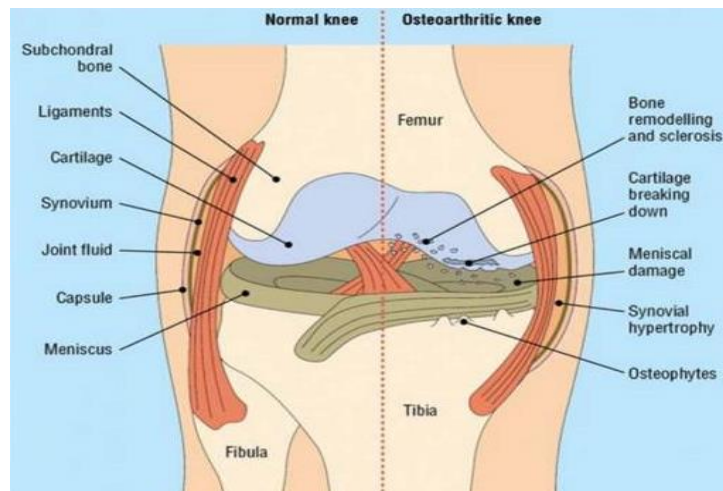


Figure 1 : Difference between healthy knee and OA knee (Poole et al, 2012). In a normal knee, there is a capsule around the joint that delimitates synovial cavity. The synovial cavity is composed of SF produced by a membrane called synovium. The subchondral bone is the bone underneath the cartilage. Between the cartilage of tibia and femur, there are two menisci (one lateral and one medial). In OA knee, all the elements of the joint can be impacted. There is a destruction of the cartilage, subchondral bone remodeling, synovial hypertrophy, formation of osteophytes and meniscal damage.

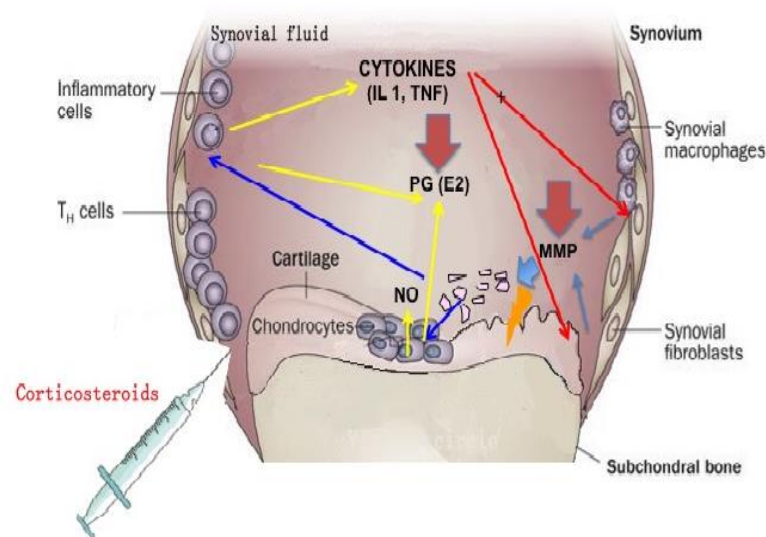


Figure 2 : Inflammation in OA joint of knee. In OA knee, cytokines and mediators are produced by chondrocytes and synovitis due to the abnormal mechanical stress. Interleukin 1 (IL-1) is upregulated and increases the expression of MMPs that degrade components of the extracellular matrix (ECM). Tumor necrosis factor- α (TNF- α) is another mediator responsible of the overexpression of some MMPs involved in the OA development (Li et al, 2015). The chronic production of nitric oxide (NO) activated by pro-inflammatory cytokine is also responsible of the degradation of the ECM and chondrocytes apoptosis in OA articular cartilage (Loeser, 2006). NO could induce the stimulation of the prostaglandin E₂ (PGE₂) by different pathways. PGE₂ could be involved with NO in the increase of chondrocytes apoptosis (Notoya et al, 2000). At low level, PGE₂ is described as having a protective effect on cartilage (PG and collagen type 2) while at a higher concentration, PGE₂ has a catabolic effect on the matrix (Attur et al, 2008).

I. Introduction

1.1 Osteoarthritis

Osteoarthritis (OA) is an inflammatory and biomechanical disease of the synovial articulations, which is characterized by gradual loss of articular cartilage (Martel-Pelletier et al, 2008).

It is chronic joint disease affecting 30-50% of adults over 65. The incidence varies with joint types: 88 per 100 000 per year for hip, 100 per 100 000 for hand, and 240 per 100 000 for knee (Bijlsma et al, 2011).

Several risk factors for OA knee have been described in humans. Body mass index, age, ethnicity and sex are the main risk factors (Fibel et al, 2015). In USA, almost half of the population over 85 years, have symptomatic knee OA (Murphy et al, 2008). The Framingham study indicated that loss of weight in women allows diminishing risk for OA (Felson et al, 1992). The physical activity may also increase the risk of OA, such as in elite long distance runners and soccer players. Fractures, muscle weakness, local pathologic changes and abnormal joint shape can also lead more rapidly to OA. Other studies show that genetic components are also involved (Johnson et al, 2014).

Symptoms of OA are pain and loss of function, which contribute to diminish the quality life of patients with the disease (Bijlsma et al, 2011). Clinical exams are the first way to detect signs of OA: reduced joint mobility, joint swelling, synovial effusion, pain at palpation and manipulation. Radiography is the most accessible tool in the evaluation of the OA joint. Joint space narrowing and osteophyte formation are generally observed by this technique. Magnetic resonance imaging (MRI) is another technique highlighting different tissues including soft tissue such as menisci in the knee joint (Braun et al, 2012).

The knee is the largest synovial joint in the body and is a very common site for OA (**Fig.1**) (Blalock et al, 2015). It is exposed to mechanical stresses that can induce damage to the cartilage and trigger inflammation of the synovium.

The inflammation of the synovium, the membrane producing synovial fluid (SF), is called synovitis and is a characteristic of OA. Proinflammatory mediators are produced in response to debris present in synovial cavity after the mechanical insult (Bijlsma et al, 2011). Mediators promote angiogenesis and production of cytokines and matrix metallo proteinases (MMPs) that induce cartilage degradation (Berenbaum, 2013). A vicious circle is created (**Fig.2**) (Loeser et al, 2012; Felson et al, 2013). The catabolic activity is amplified and results in a progressive loss of cartilage.

An anatomical characteristic of the knee is the presence of other cartilage structures called menisci. They are structures very important for the biomechanical mechanism of knee. The relationship between OA and menisci seems to be complex (Englund et al, 2007). Meniscal tears in healthy knee could eventually lead to OA (Roos et al, 1995). The increased loading of joint cartilage is certainly the cause of OA development. OA is also described as having an impact on the integrity of menisci. In summary, several elements show there is a relationship between meniscal lesions and development of OA (Noble et al, 1975; Englund et al, 2007).

To treat OA, the combination of pharmacological and non-pharmacological treatment is generally useful (Alshami et al, 2014). Recently, the guidelines for the non-surgical treatment of knee OA (Guidelines OARSI) stated that the most agreed non-pharmacological modalities are biomechanical intervention, self-management, education, strength training and weight management.

Intra-articular (IA) injections can also be used. Their main effect is to reduce pain. Hyaluronic acid (HA) and corticosteroids (CS) seem to have the same size effect at three months post injection (Bannuru et al, 2015). According to the OARSI (Osteoarthritis Research Society International), intraarticular corticosteroids (IACS) seem to be an efficient treatment for pain, but are only short term (McAlindon et al, 2014). The short term (4 weeks) benefits of IACS injection has been confirmed in a recent meta-analysis (Bannuru et al, 2009; Ayhan et al, 2014).

There are several classes of CS: dexamethasone, betamethasone, triamcinolone, hydrocortisone and methylprednisolone. CS have two modes of actions. The first action is to limit the capillary dilation and the permeability of the vascular structures and consequently reduce the accumulation of polymorphonuclear leukocytes and macrophages. The second action is to prevent the synthesis of several inflammatory mediators (Ayhan et al, 2014; Rathod et al, 2014). CS act by binding on intracellular glucocorticoid receptors (GRs) and exert their effect as transcription factors in cells. In fact, CS can inhibit synthesis of inflammatory mediators like IL-1 β , TNF- α and cyclooxygenase-2 or degrading enzymes such as MMPs implicated in the pathophysiologic process of OA (Caron, 2005; Lu et al, 2011). Triamcinolone acetonide (TA) and hexacetonide (TH) seem to have the longer effect though pharmacokinetics/pharmacodynamics (PK/PD) are not widely described (McIlwraith et al, 2010).

Currently, the optimal dose for the utilization of each CS has little agreement (Douglas, 2012). In addition, there is not enough data to confirm that they have positive or deleterious effects on articular cartilage. Though it is often said that animal studies could provide useful information about the effects of CS on cartilage, a recent systematic review demonstrated that all relevant studies conducted between 1965 and 2014 have not provided enough quantity of evidence about the effect of CS on cartilage (Vandeweerdt et al, 2015). Moreover, there were several weaknesses in the methodology of the previous studies. For example, it was not proved that animals that were selected had comparable cartilage at baseline. In addition, the dosage regimen of IACS was very variable making comparison between studies difficult. Some studies demonstrated that there is a toxic effect with large quantity doses and with high frequency doses on animals. In consequence, higher concentrations and multiple injections could have a catabolic effect while lower doses and lowest regimen could have positive consequences on cartilage, while keeping an anti-inflammatory role (Pelletier et al, 1989).

Moreover, the effect of CS on menisci was addressed only in few studies (Rokkanen et al, 1967; Ishikawa et al, 1981; Chu et al, 2008). Data on the rabbit suggest that CS could have deleterious effects in menisci. An inhibition of the synthesis of GAGs, proteins and collagen was observed with IACS injection. It would therefore affect the properties of the meniscus (Ishikawa et al, 1981). However, there are too few studies on the subject to draw conclusions.

Better understanding of changes of articular and meniscal histological structure after CS injection is important.

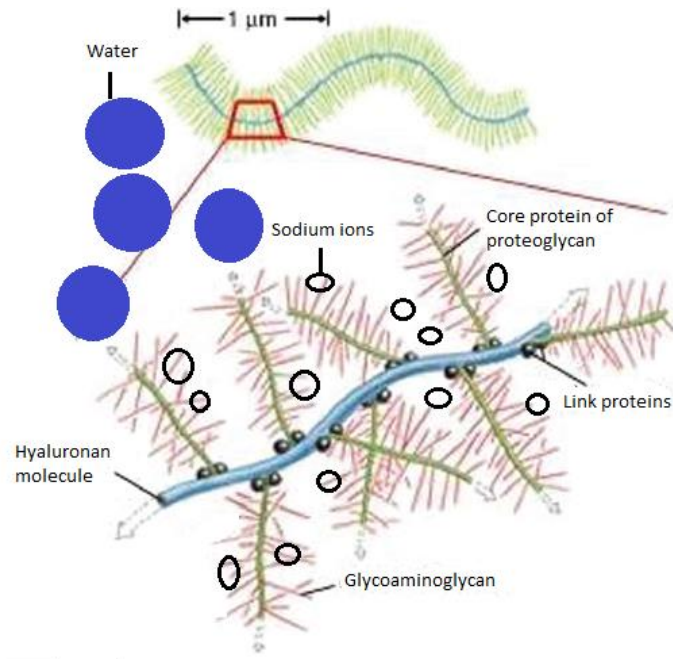


Figure 3: Representation of proteoglycans (PGs) aggregates (adapted from Fox et al, 2012). HA molecules bind with PGs to form aggregates. The negatively charged carboxyl group of glycosaminoglycan (GAG) attract sodium ions. The result is creation of an osmotic imbalance attracting water into the cartilage.

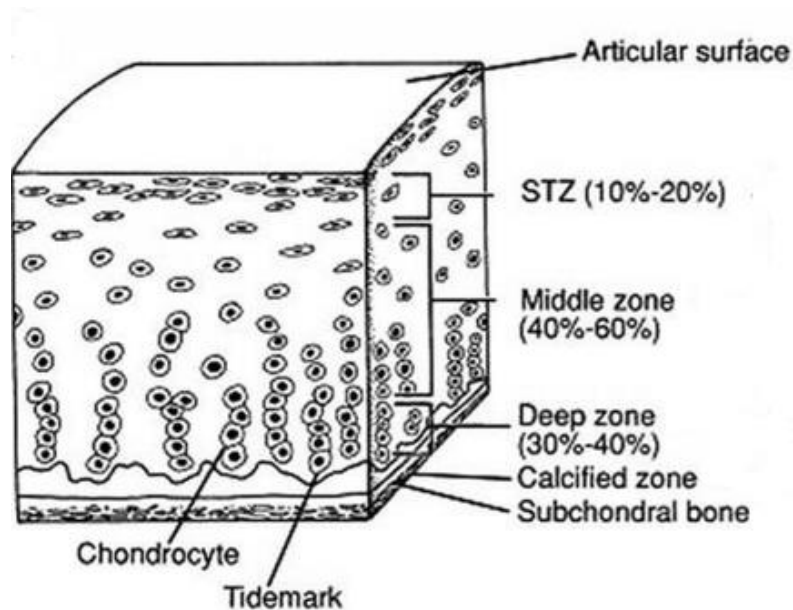


Figure 4: The different zones of articular cartilage (Fox et al, 2009). The upper layer in the articular cartilage is a thin superficial layer. The second layer is in the middle of uncalcified cartilage and is called the middle zone. The deep zone is located just before tidemarks marking a transition with the calcified zone. The subchondral bone is the structure just after the calcified zone.

II. Relevant background

2.1 Histological structure of articular cartilage

The articular cartilage is a hyaline cartilage composed of an extracellular matrix (ECM) synthesized by cells named chondrocytes. ECM is composed principally of water, proteoglycans (PGs) and collagen (Fox et al, 2009).

The most important macromolecule is collagen representing approximately 60 % of the dry weight. Different types of collagen are present in the ECM but collagen type 2 represents 95% of total collagen. The basic structural unit of the collagen is a triple-stranded helical molecule. These molecules of collagen pack together to form thin fibrils and help tissue to resist stretching (Lodish et al, 2000).

The second most important macromolecule is proteoglycan (PG). PGs are protein cores attached covalently with glycosaminoglycan's (GAGs). GAGs are formed by repetition of disaccharides: the first molecule is an uronic acid or a galactose and the second is an amino sugar (Fox et al, 2009). Carboxyl groups of GAGs are negatively charged and attract Na⁺ ions. This high concentration of Na⁺ can attract water and lead to a high pressure inside cartilage (Pearle et al, 2005; Lu and Mow, 2008). The most important PG in hyaline cartilage is aggrecan. Interaction with HA allows forming PG aggregates (**Fig.3**). Other PGs are mainly known to interfere with collagen. Glycoproteins and non-collagenous proteins also compose the matrix.

Water is the most abundant component of articular cartilage and contribute to its high resistance to loads. Only a little part of water inside cartilage is attached with ECM to form gel, the other part is free and can move inside the matrix. With knee loading, the cartilage is pressurized and the fluid flows out of the ECM. After loading, the interstitial fluid can come back inside the matrix (Fox et al, 2009). This gives to articular cartilage the property to act as a shock absorber in the knee (Hauser, 2010).

Histologically, the articular cartilage is divided in different zones. The first zone is a thin superficial layer (10-20% depth). Parallel organization of collagen fibers gives the property to resist shear stress in deeper layer. The middle zone is composed of thicker collagen fibrils in radial orientation. This zone represents roughly 40-60% of the total cartilage and is the first line of resistance to compressive forces. The largest diameter collagen fibrils are present in the deep zone (30-40 % depth) and are oriented perpendicular to the calcified cartilage. The high concentration in PG in this zone allows a greatest amount of resistance. The deepest layer is the calcified cartilage zone. The tidemark separates the non-calcified cartilage from the calcified cartilage (**Fig.4**) (Fox et al, 2009; Goldring and Marcu, 2009).

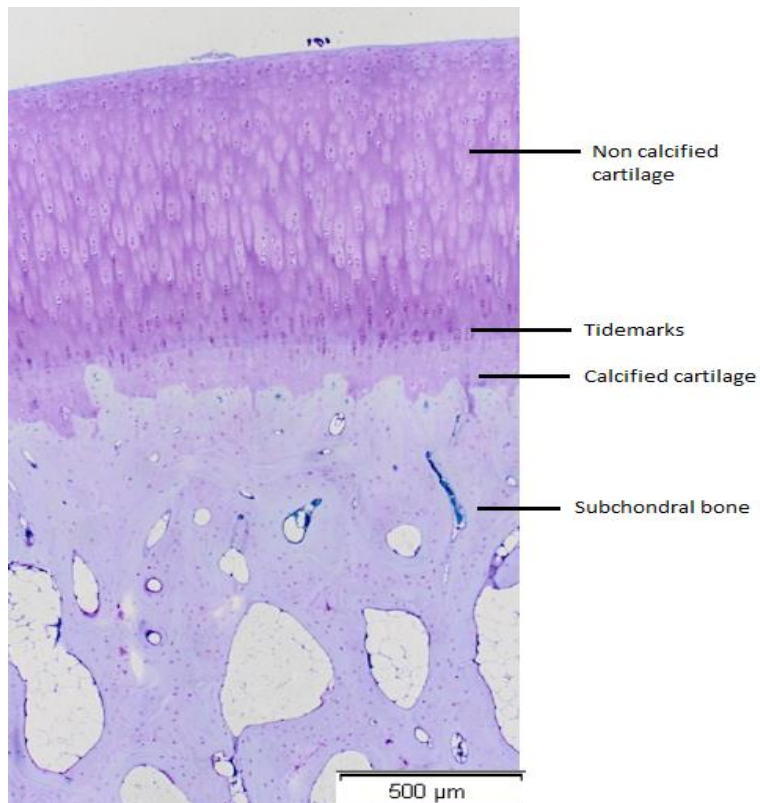


Figure 5: Histological representation of a healthy cartilage. The first zone is the non-calcified cartilage which is distinguished of the calcified cartilage by tidemarks. Below the calcified cartilage is the subchondral bone.

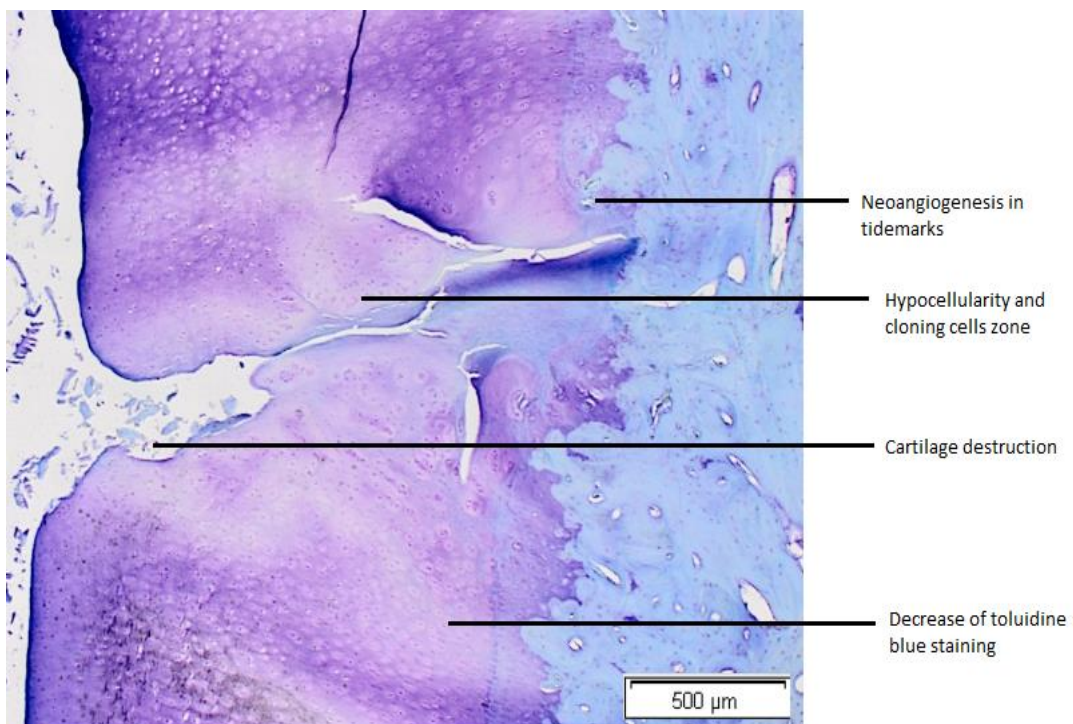


Figure 6: Histological representation of a diseased cartilage. This picture shows a neoangiogenesis in tidemarks, zones of hypocellularity, a destruction of cartilage and a decrease of toluidine blue staining.

Chondrocytes are not arranged in the same way according to the zone. In the articular surface, chondrocytes are flattened and arranged in one or two layers. In the middle zone, chondrocytes are round and dispersed in the ECM. The columnar orientation of chondrocytes is visible in the deep zone. In the calcified zone, chondrocytes are few and hypertrophic (Fox et al, 2009). Chondrocytes are responsible of the homeostasis of ECM in producing matrix components. These cells are sensitive to different stimuli such as mechanical stress, oxidative stress or changes in growth factors responses (Goldring and Marcu, 2009).

An example of normal cartilage is shown in Figure 5 (**Fig.5**). Guidelines for microscopic assessment of articular cartilage has been published by OARSI (Little et al, 2010). Normal cartilage in histology is characterized by a good density of chondrocytes, an intense interterritorial staining of toluidine blue, no chondrocytes cloning and no structural modification in cartilage and subchondral bone plate.

In OA several changes have been described. During progression of the disease, processes of repair are not sufficiently effective to compensate structural damages. This phenomenon leads to fissures and fibrillations (erosion of the cartilage structure) in the articular cartilage (**Fig.6**) (Sharma et al, 2013).

About cellularity, there is firstly an abnormal proliferation of chondrocytes leading to chondrocytes clusters formation. The intensity of chondrocytes cloning is characterized by doublets, triplets and cells nest. Clusters of chondrocytes correspond to a final attempt to repair ECM (Poole et al, 1991). After this proliferation, the next step is a decrease of chondrocyte population to reach at the end a non cellularized cartilage (Little et al, 2010). The hypocellularity is a characteristic of OA disease and could be explained by an increase of chondrocytes apoptosis (Sharif et al, 2004).

There is also a decrease in toluidine blue staining. Toluidine blue is basic metachromatic dye with a high affinity for acidic component like GAGs in PGs (Sridharan and Shankar, 2012). It therefore reflects a decline in the content of GAGs and PGs, a characteristic of OA disease. This decrease in PG content can be at the origin of an increase in swelling pressure of cartilage (Han et al, 2011).

The last criteria is the number of tidemarks and changes in the vascularization of subchondral bone. Tidemarks are elements that separate hyaline cartilage from calcified cartilage. It's the accumulation of debris from apoptosis of chondrocytes or ECM degradation. The multiplicity of tidemarks seems to be reported with advance of disease. The remodeling of subchondral bone can be up to 20 times increased in an OA knee (Sharma et al, 2013). With increasing of OA severity, there is a raise of vascular density at the osteochondral junction. The sensory nerve growth seems to be facilitated by vascular invasion. Moreover, the penetration of blood vessels inside the articular cartilage could lead to its ossification.

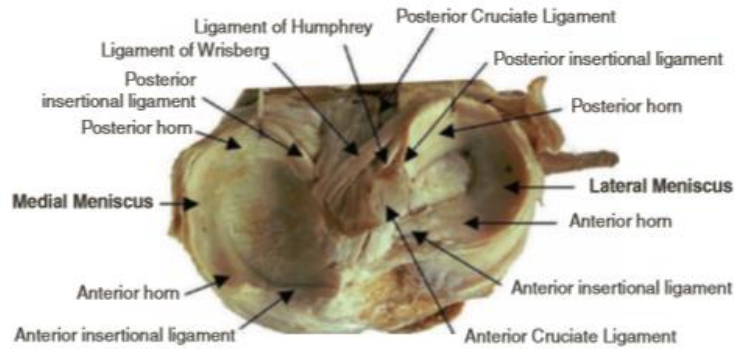


Figure 7: Cross section in the meniscus (Beaufils and Verdonck, 2010). Menisci are anchored at its anterior and posterior horns to the tibia by meniscotibial ligaments. Though being attached at their extremities, their body remain mobile. The lateral meniscus is less firmly attached to the joint capsule than the medial one (Englund et al, 2009; Howell et al, 2014). Meniscomfemoral ligaments (Humphrey and Wrisberg ligaments) connect the posterior horn of the lateral meniscus to the lateral aspect of the medial femoral condyle (Howell et al, 2014). The anterior meniscomfemoral ligament has the name of Humphrey and passes anterior to the posterior cruciate ligament. The posterior meniscomfemoral has the name of Wrisberg and passes posterior to the posterior cruciate ligament. The meniscomfemoral ligaments could have a role in the movement of the posterior horn of the lateral meniscus during flexion of the knee (Gupte et al, 2002). They are several intermeniscal ligaments. The anterior transverse meniscal ligament joins the anterior horn of the medial meniscus to the anterior horn of the lateral meniscus and the posterior transverse meniscal ligament connects the posterior horn of the two menisci.

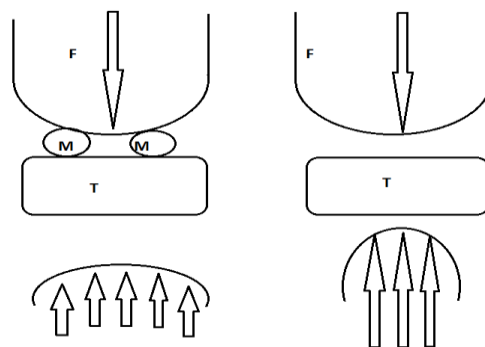


Figure 8: Distribution of loading with menisci (left) and without menisci (right) (adapted from Gray's p. 1405). F, Femur. M, meniscus. T, Tibia. There is a better area of distribution loading with meniscus. Without meniscus, there is an increase in contact forces. The concave structure of the menisci has an important role in the joint stability between femoral condyles and tibial plateau and increases the congruence between the two surfaces (Fox et al, 2012). Moreover, menisci have viscoelastic properties that support the compression by the axial tibiofemoral during knee-flexion during daily activity (Verdonck et al, 2005; Amiri et al, 2006; Makris et al, 2011).

2.2 Histological structure of meniscal cartilage

The knee is characterized by the presence of two semicircular fibrocartilaginous structures interposed between the femoral and tibial condyles called the menisci (Englund et al, 2012; Mezhov et al, 2014). They are essential for joint stability, distribution of contact forces, joint lubrication, and proprioception (Englund et al, 2012; Howell et al, 2014).

There are two menisci, medial and lateral, covering approximately two thirds of the articular surface of the tibia (Englund et al, 2009). The lateral meniscus covers a larger portion of the tibial articular surface than the medial meniscus. The medial meniscus is approximately 3 cm wide and 4 to 5 cm long and the lateral meniscus is approximately 3 cm wide and 3 to 4 cm in length (Athanasίου et al, 2009). Each meniscus is composed of a body and two horns (the extremities). The posterior horn is larger than the anterior horn (Englund et al, 2009). The menisci are anchored to the tibia and femur by several ligaments (**Fig.7**).

The transmission of the joint force from the femur to the tibia is the main role of the menisci in the knee (Verdonck et al, 2005). The meniscus has biochemical properties to resist to the force exerted on the tissue like shear, tension and compression (**Fig.8**). The menisci may also have a role in lubrication and nutrition in compressing SF into the articular cartilage (Arnockzky et al, 1988). Proprioceptive information in the knee joint can be detected by neuronal elements of menisci and therefore is maybe involved in proprioception of the knee (Fox et al, 2012).

Histologically, menisci are composed as cartilage tissue of a dense ECM. Meniscal cells as chondrocytes synthesize this ECM made principally of collagens and PGs. These elements constitute a network in which water is entrapped. As it is the case for articular cartilage, water is the most abundant element in meniscal cartilage and makes about 70% to 75% of menisci (Fox et al, 2012). The tissue's viscoelastic behavior is the result of flow of the water fraction in and out of the collagen and PG network during loading (Fithian et al, 1990).

Three populations of cells can be distinguished according to their position in the meniscus. In the outer zone (also called red-red zone because of its more abundant vascularization), cells have an oval shape with disproportionately large nucleus and have similar appearance than fibroblasts. Fibroblasts are part of the connective tissue and secrete component of the ECM. Fibroblast-like cells facilitate communication with other cells to maintain homeostasis and help cells to respond to different type of mechanical loading. Cells in the inner portion (also called white-white zone due to the absence of vascularization) are more round with large amount of endoplasmic reticulum and are named fibrochondrocytes.

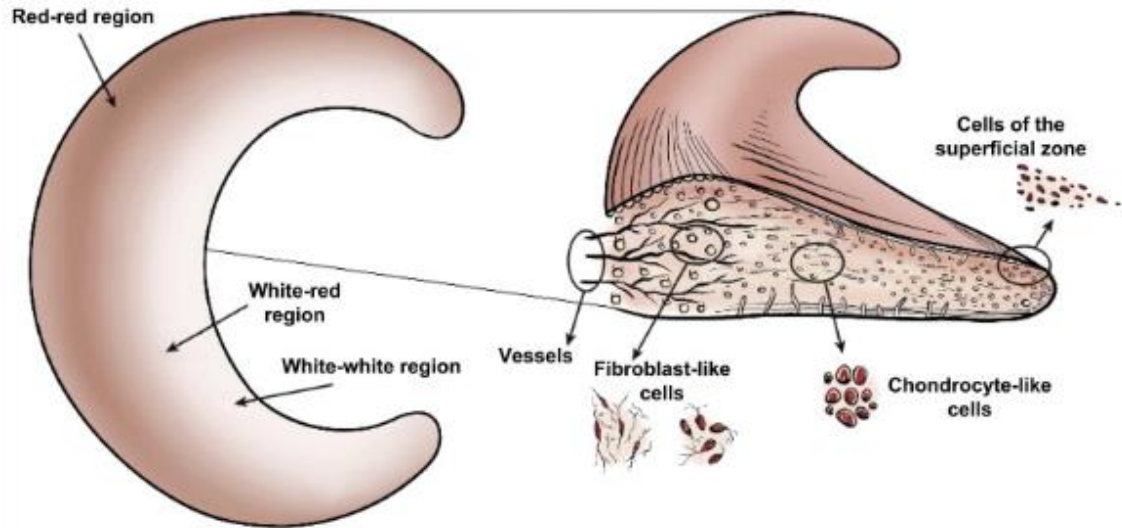


Figure 9: The different cell types and vascularization area in the meniscus (Makris et al, 2011). This is a section in the middle part of the meniscus. Three types of cells are present: chondrocyte-like cells in the inner zone, fibroblast-like cells in the outer zone and progenitor cells in the superficial zone. According to the degree of vascularization, three regions can be distinguished: red-red region, white-red region and white-white region.

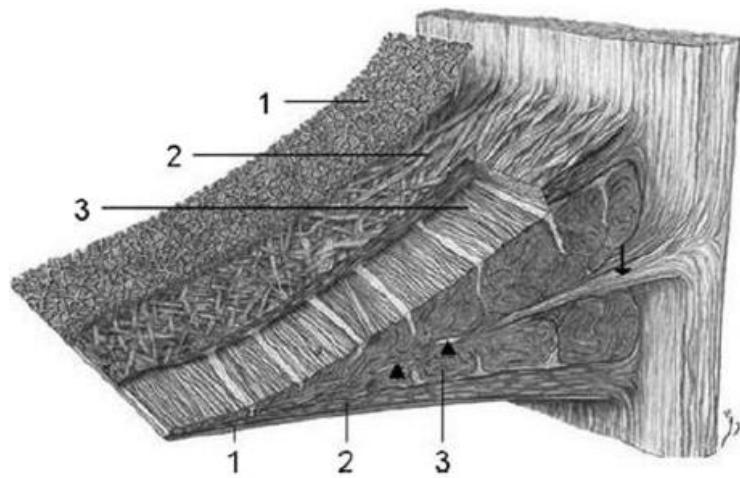


Figure 10: Orientation of collagen fibers in the meniscus (Petersen and Tillmann, 1998). This is a section in the meniscus with the inner part to the front of the drawing. 1. The superficial network of collagen with radially orientation, 2. Intermediate layer with few radial fibrils collagen and circumferential fibrils collagen, 3. The central main layer with circular orientation of fibrils collagen.

Their role is mainly to synthesize collagen type 1 (with small amount of type 2 and type 3). Fibrochondrocytes properties are important to resist to compressive forces. There is a third population at the superficial zone of the meniscus. These cells have a fusiform morphology without extensions. These cells are possibly specific progenitor cells with regenerative capabilities (**Fig.9**) (Mcdevitt et al, 1990; Hellio Le Graverand et al, 2001; Melrose et al, 2005; Van Der Bracht et al, 2007).

The main insoluble fibrillar component of the ECM is collagen. The majority of collagen in the meniscus is type 1 in contrast to articular cartilage which is made of type 2. Collagen type 1 has fibrils larger in diameter than collagen type 2. Collagen type 2 is oriented randomly in the PG matrix and is important to resist in large deformation. Collagen type I is more organized and has an important tensile strength (Lodish et al, 2000). The softest connective tissue is collagen type 3 and is frequently in association with collagen type 1 (Fox et al, 2012).

The matrix allows resisting tension, compression and shear stress (Fithian et al, 1990). The tensile properties of the circumferential fibers of collagen are 3 to 10 times higher than those of radial fibers and are directly correlated to the tissue's behavior in tension and compression (Fithian et al, 1990; Masouros et al, 2008). The collagen fibers are predominantly orientated circumferentially but a smaller amount of fibers lying at the surface are radially oriented. At the surface of the meniscus, there is a collagen fibrillary network to aid in distribution of shear forces (**Fig.10**) (McDevitt et al, 1990; Fox et al, 2012).

In the composition of PG, there are some similarities with those observed in cartilage. As in hyaline cartilage, the major large PG is aggrecan. About small PG, the two main are biglycan and decorin in menisci (Fox et al, 2012). These proteins are attached with GAGs like chondroitin-6-sulfate or dermatan sulfate in meniscal tissue. The function of PGs in menisci is identical to articular cartilage namely absorb water that will participate to resistance to compression (Herwig et al, 1984; Scott et al, 1997). The proportion of GAGs and PGs varies with the localization. The content in the inner two-thirds is higher than the outer one-third (Sanchez-Adams et al, 2011).

The last component of meniscus matrix is adhesion glycoproteins. They are indispensable to link ECM components and cells. The most important glycoproteins in human are fibronectin, thrombospondin and collagen VI (Miller et al, 1991). As it is known in knee cartilage, HA is important to stabilize the interaction with PG (Fox et al, 2012).

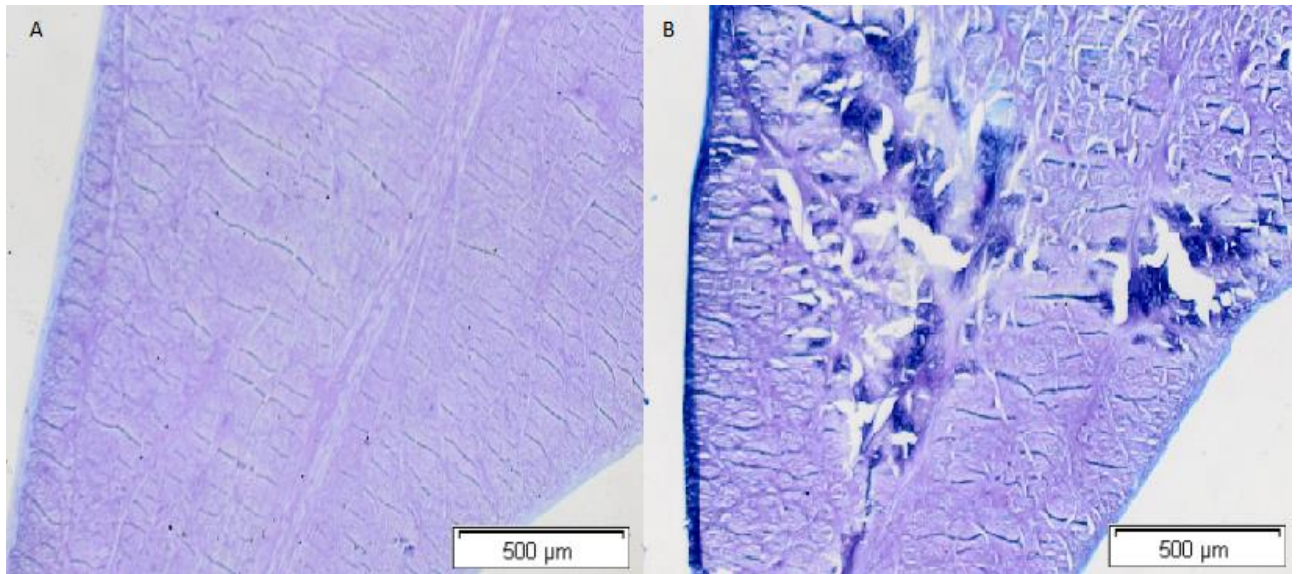


Figure 11: Histological representations of menisci. A: a healthy meniscus without loss of tissue and normal content in cells, PG and collagen; B: a diseased meniscus with loss of tissue and matrix disruption.

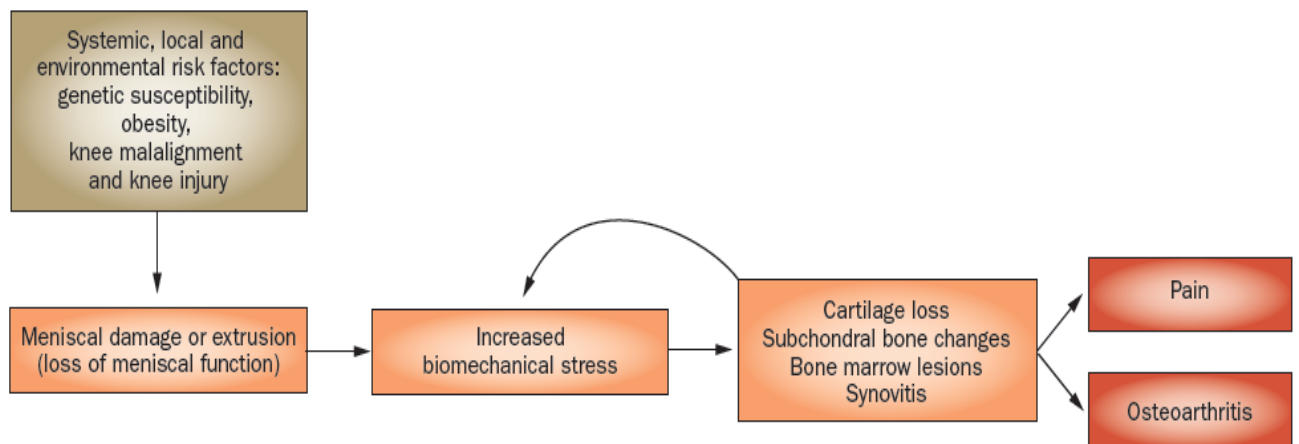


Figure 12: The role of meniscal lesions in the OA emergence (Englund et al, 2012)

Meniscal disease is common. The mean annual incidence of meniscal lesions is of 66 per 1000000 inhabitants. The age significantly increases the chances of having meniscal tears (Baker et al, 1985). Meniscal tears have been described as having a relation with the development and progression of OA (Sharma et al, 2008). Indeed, it's important to note that the risk of OA is much higher in knee with meniscal lesions (Englund et al, 2009).

Some tears in the menisci are more associated with OA. This is the case when the meniscus splits vertically and parallel to the circumferentially oriented collagen fibers (Englund et al, 2009). Meniscal tissue has a protective role on cartilage integrity suggesting relationship between the damage and structural progression of OA (Chang et al, 2011). OA is also described as having an impact on the integrity of menisci. In fact, OA could lead to meniscal tears and accelerate the process of the disease (Roos et al, 1995). Actually, there is not enough elements to know if the development of OA is due to meniscal lesions or the other way round (**Fig.12**) (Englund et al, 2009).

No histological scoring for menisci exists for sheep. The score for histological assessment of OA in dog's menisci, published by OARSI, can be used. As it is represented in Figure 11 (**Fig.11**), the main criteria of a healthy meniscus are: a normal tissue architecture without disruption or complete loss, a normal content in cells and matrix and no proliferative response at meniscal-synovial junction.

According to the OARSI score in dogs, a histopathologic meniscus is defined as having a loss of architecture tissue, a disruption in cells, PG and collagen and a proliferation of cells at meniscal-synovial junction (**Fig.11**). Only few studies have been realized on histology changes of OA menisci. It seems to have a more severe fibrocartilagenous disruption in menisci of humans with the disease. The cell distribution in pathological menisci is very varied. The area are either hypercellular, hypocellular or acellular. In the regions of severe meniscus matrix disruption, abnormal cell cluster and hypertrophic single cells have been observed (Pauli et al, 2011).

OA induces also changes in the biochemical composition of menisci (Pauli et al, 2011; Sun et al, 2012). In the middle and the deep zone of OA meniscus, a decay of the amount of collagen type 1 is visible. The same phenomenon is observable in the surface, middle and deep zones of osteoarthritic menisci for collagen type 2. By comparing to normal menisci, PG content increases in osteoarthritic menisci. The major PG in the meniscus is aggrecan and is much higher in OA menisci deep zone (Sun et al, 2012).

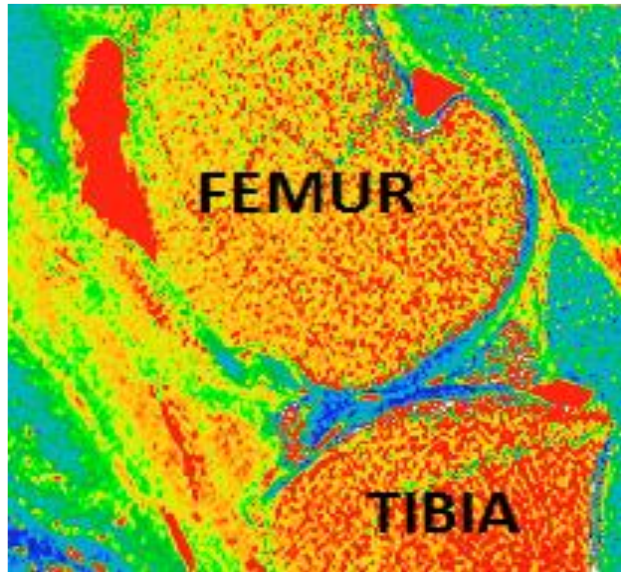


Figure 13: Color code scoring of T2 mapping images. The color code represents different transverse relaxation time of water protons. Blue color indicates areas of short T2 time relaxation and red color indicates long T2 time relaxation.

Magnetic resonance (MR) imaging (MRI) is a non-invasive technique used to observe the progression of cartilage lesions. To assess the biochemical composition of cartilage, MR composition imaging has been developed in order to assess the state of cartilaginous structure in longitudinal studies in vivo. T2 mapping is one of these techniques and is based on the calculation of transverse relaxation time. This reflects the ability of water proton to move inside the matrix (**Fig.13**). In consequence, modification of the matrix content or in the matrix organization can be potentially detected by T2 mapping (Watrín-Pinzano et al, 2004). As said earlier, meniscal degeneration is generally characterized by a loss of PGs, collagen and decrease in water content (Liu et al, 2015). Study on articular cartilage have shown that T2 mapping values are principally influenced by water content and collagen organization. T1p (rho) mapping being the most suitable technique to observe PG content, but this sequence is not often available (Hontoir et al, 2015). In previous studies, T2 mapping has shown to be a sensitive technique for detection of meniscal lesions. T2 mapping could also be used to know the biochemical composition of menisci in early OA menisci but more researches are necessary (Baum et al, 2013).

III. Research question

There is not enough quantity of evidence about the impact of CS on menisci and articular cartilage. TH has been cited like the more efficient CS with the more long-term effect, and a potential protective effect. This master thesis assessed the effect of TH on articular and meniscal cartilage at a dose commonly used by clinicians i.e. 25 mg.

The objectives were to design (part 1 of the master thesis) and to conduct (part 2 of the master thesis) a controlled trial in an ovine animal model to determine the effect of CS at 25 mg

- (1) on the histological structure of articular cartilage
- (2) on the histological structure of meniscal cartilage
- (3) on meniscal composition assessed by compositional MRI imaging (T2 mapping)

IV. Material and methods

4.1 Ethical statement

The experimental protocol (14/226 VA) was approved by the local ethical committee for animal welfare. All sections of this master thesis adhere to the ARRIVE (Animal Research: Reporting of In Vivo Experiments) Guidelines for reporting animal research. The only painful procedure during the experiment was the indwelling of an intravenous catheter in a cephalic vein for anesthesia. All other interventions (imaging, IA CS) were operated under general anesthesia. Pain and wellbeing were assessed using a validated scale evaluating the comfort, movement and herd behavior of animals (Dowd et al, 1998; Shafford et al, 2004).

4.2 Experimental animals and selection criteria

Large animals like sheep share more similarities with human in terms of macroscopic and microscopic anatomy (Cake et al, 2008). Sheep are commonly used for studying pathogenesis and treatments of OA (Little et al, 2010).

In this study, female cross Texel sheep, ranging from 2 to 10 years and weighting between 60 and 80 kg, were used. They were animals retired for a reason other than musculo-skeletal diseases. Animals came from the Ovine Research Centre of the University of Namur. Joint status was assessed at baseline by clinical examination (detection of pain, heat and swelling by palpation; assessment of locomotion), and computed tomography arthrography (CTA). Only animal with healthy joints were eligible for the study. A healthy joint refers to the absence of lameness and signs of inflammation on clinical examination, and absence of cartilage or subchondral bone abnormalities at CTA.

4.3 Housing and husbandry

The animals were maintained in an open paddock during the study, except immediately after the interventions (surgery, imaging) when they were kept in a 6 x 6 m stable for 7 days. They were allowed to walk freely.

4.4 Study design, allocating animals to experimental groups and blinding

Sheep were numbered and the opposite stifle joints (left or right) were randomly assigned into Saline group (0.9%, 1.25 mL) and TH group (25mg, Hexatrione 2%, 1.25 mL) using a software Randomization (<http://www.randomization.com/>). Allocation to the groups and IACS injections were performed by a clinician not involved in the assessment of experimental outcomes. CTA and all in vivo and postmortem investigations were conducted by researchers who were not aware of the interventions.

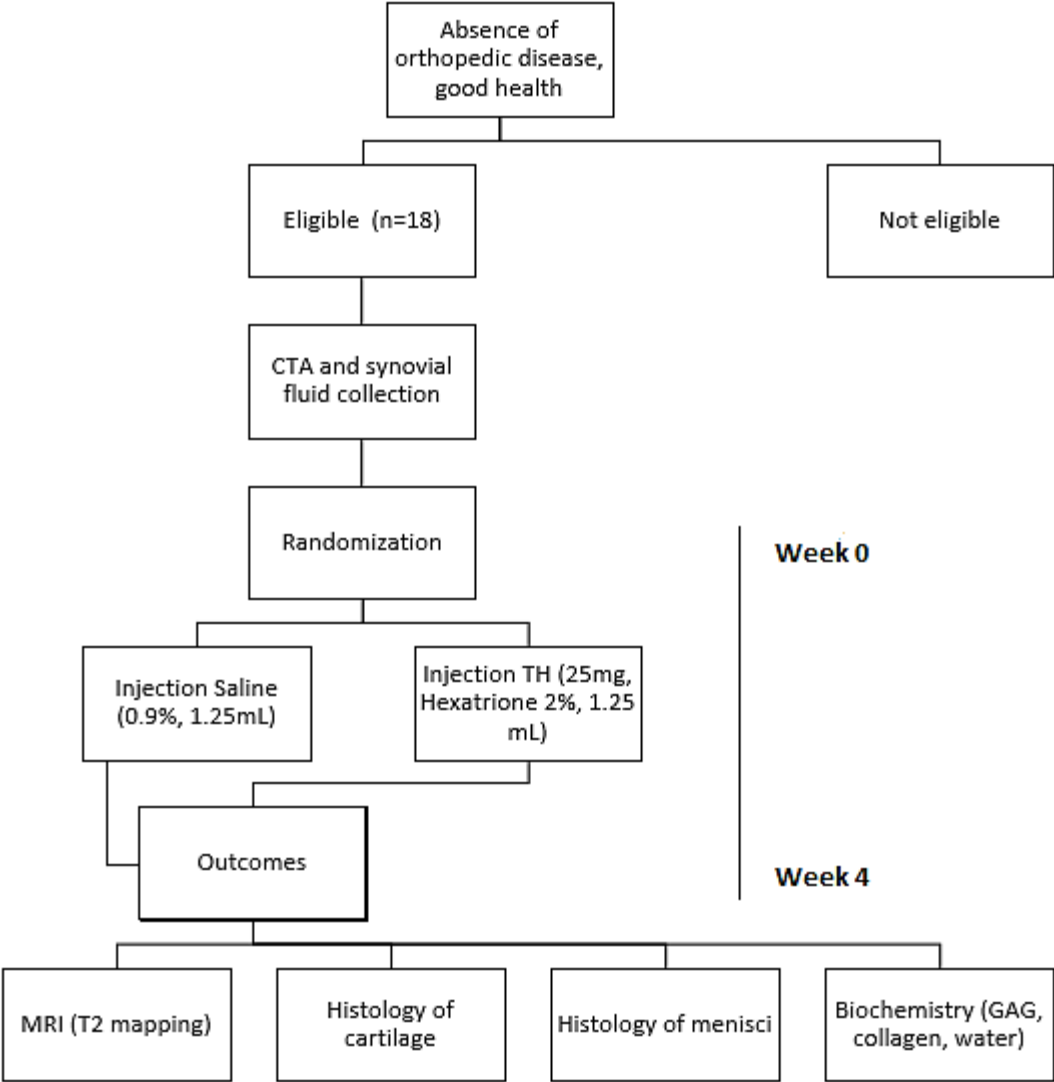


Figure 14: Flow chart for the study design

Table 1: Numeric ranking scale for assessment of post-operative pain in sheep

Criteria		Score
Comfort	Awake, interested in surroundings, patient recumbent or standing, chewing cud, eating	0
	Awake, standing or recumbent, not interested in surroundings, not chewing cud, reduced appetite	1
	Lethargic, depressed appearance, ears dropped, not chewing cud, not eating	2
	Head down, very lethargic, ears stay dropped when aroused, not chewing cud, bruxism (grinding teeth)	3
	Recumbent, no response when approached, fixed look and staring, or eyes half closed, little response when gently prodded, bruxism	4
Movement	Normal ambulation, full weight-bearing, no lameness	0
	Slight lameness on operated limb, toe-touching on all steps	1
	Lameness on operated limb, toe-touching on some, but not all steps	2
	Lameness on operated limb, not toe-touching on all steps when walking voluntarily, but will toe-touch when herded	3
	Lameness on operated limb, not toe-touching on all steps when walking voluntarily and when herded	4
Flock behavior	Normal, moves with the rest of the flock	0
	Mild changes, lethargic or lags behind rest of flock when flock is moved, but eventually joins them voluntarily	1
	Moderate changes, lags behind rest of flock when flock is moved, but eventually joins them if encouraged to do so	2
	Severe changes, no interest in rest of flock; always separated from flock	3
Total		0-11

4.5 Experimental procedure

4.5.1 Lameness evaluation and gait analysis

A validated scale for evaluating the comfort, movement and herd behavior of animals was used to assess pain and wellbeing (Dowd et al, 1998; Shafford et al, 2004). The basic welfare parameters for each individual were provided the first week. During the experiment, the evaluation was performed twice a day (morning and evening) by an experienced staff. Results were collected in a clinical examination record (**Table 1**).

Other clinical signs such as joint swelling, local heat, pain at palpation and flexion were recorded the day of CS injection, and then every week till euthanasia.

4.5.2 Anesthesia

In compliance with animal's wellbeing, sheep were anesthetized for CTA and CS injections. To minimize the risk of error and bloat, sheep were fastened 12 hours before anesthesia. Sheep were indwelt with an intravenous catheter (Terumo 21g 1½) in a cephalic vein before anesthesia. After sedation with 150µg/kg xylazine and 150µg/kg diazepam, sheep were anesthetized with IV pentobarbital at dose of 3mg/kg for induction and 10mg/kg/h for maintenance. After induction, sheep were placed in sitting position. Mouth was opened and an endotracheal tube (size 8.0) was placed with a laryngoscope. The tube was connected to an ambubag and animals were insufflated with 6 mL/min oxygen. During anesthesia, several parameters were monitored every 5 min including heart rate, respiratory rate, SpO₂ (pulse oxymetry) and depth of anesthesia (by eyelid and corneal reflexes). After recovery from surgery, animals were maintained in an open paddock during the experimental period.

4.5.3 Injections

After anesthesia, animals were placed in dorsal recumbency. A 21g 1½ needle was inserted into the joint by a paraligamentous technique after shaving and disinfection. The needle was inserted laterally to the patellar ligament. Fluid was collected if possible. Then the injection (saline 1.25ml or triamcinolone hexacetonide 25mg, 1.25ml of 2% Hexatrione) was performed. After injection, sheep were placed in a dedicated stable with straw and monitored until recovery.

4.5.4 Euthanasia

Animals were euthanized by injection in the cephalic vein of 20 ml T61 at 4 weeks after injection. Hind stifles were disarticulated at the level of the coxo-femoral joint and collected within 6 hours of euthanasia.

4.6 Experimental outcomes

4.6.1 CTA imaging

Animals were placed in sternal recumbency. A volume mix of 7 mL of ionic contrast medium (320mg/ml ioxalate meglumine and sodium ioxalate; Hexabrix 320, Guerbet, Aulnay-sous-Bois, France) and 13 mL of saline at 37°C were injected in the femoro-patellar compartment. To ensure a homogeneous cover of the joint surfaces with the contrast medium, stifles were flexed and extended 30 times. The animals were scanned with Emotion 6 CT (Siemens). The acquisition protocol was: 130KV, 80mAs, pitch 0.4, collimation 0.63mm and rotation time of the tube 0.6s. An increment of 0.3mm was used to reconstruct image of 0.6 mm. Coronal, sagittal and transversal reformations was obtained from isotropic volume of images. Field of view extended from the base of the patella to 6cm below the tibial plateau. In-plane resolution was 0.2mm and images were reconstructed on a 512-512 matrix. Images were then transferred on a medical digital imaging system (PACS, TELEMIS).

CTA images were performed at the start of the experimentation in order to know the baseline of cartilage. After analysis of images, sheep with absence of score 3 or 4 were eligible. Score 0 was given when a sharp line of contrast material was identified on the cartilage surface, without substance loss; score 1 was defined by a loss of the sharp and smooth contour of the cartilage surface; score 2 was defined by the penetration of contrast material into superficial half of cartilage thickness but not reaching the subchondral bone; score 3 and 4 were attributed for penetration reaching the SB with the diameter less or more than 5mm respectively.

4.6.2 Magnetic resonance imaging (MRI)

After euthanasia but before dissection, MRI was realized. A 3.0 Tesla Siemens Verio 6 was used. T2 mapping (sagittal and coronal) was performed. A knee 6-channel coil was used (Siemens, Germany). Images were transferred on Telemis for analysis. T2 mapping and measure of T2 times was performed.

In recent years, compositional imaging techniques using MRI have been developed to assess the biochemical composition of cartilage.

MRI or Nuclear Magnetic Resonance (NMR) aims to identify the electromagnetic signal of the protons of the nuclei of specific atoms, commonly the hydrogen atoms, placed in a magnetic field, after they have acquired higher energy from a proton-adapted radiofrequency pulse (RF) which causes them to resonate. After the RF pulse has ceased, protons in the higher energy state can return to the lower state by two processes. They can interact with magnetic fields in their environment and transfer their energy. This transfer of energy is called longitudinal (T1) relaxation (or T1 recovery). Protons can also stop processing in phase under the influence of other adjacent protons. It is an entropic process causing a decrease in phase coherence, and an increase in global chaos or entropy. This phenomenon is called transverse (T2) relaxation (or T2 decay). These processes have a specific duration.

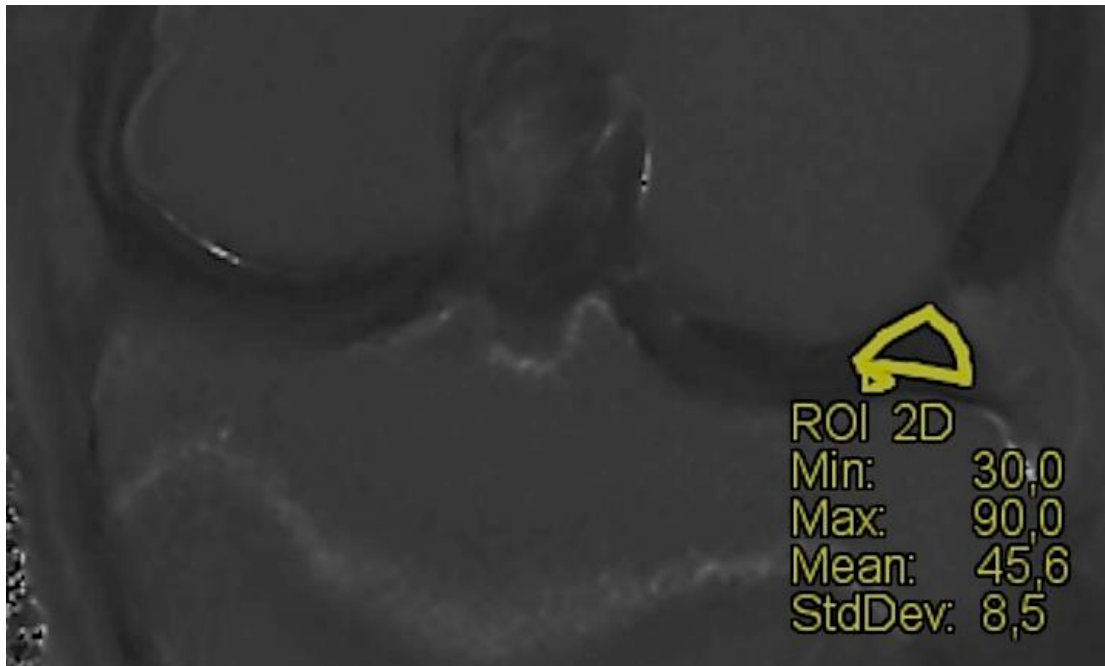


Figure 15: Coronal image of lateral meniscus in left knee obtained with MRI. Region of interest (ROI) was placed in order to calculate the mean of T2 mapping inside the middle part of this meniscus.

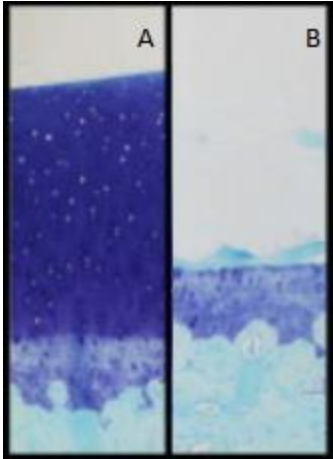
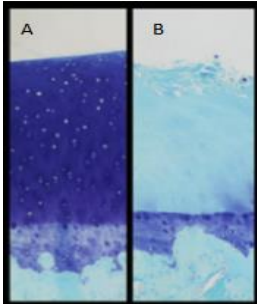
The recovery of the protons' initial energy state is therefore specified by two relaxation times (time constants), T1 and T2 that are characteristic of the composition of the tissue

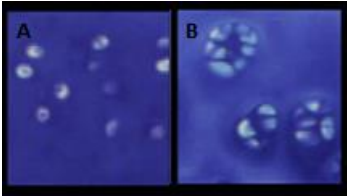
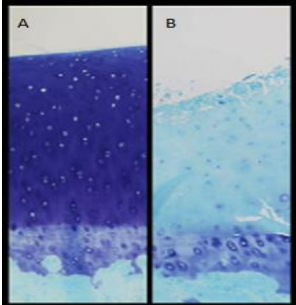
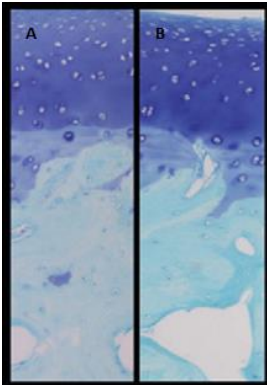
Mobility of water protons varies with tissue (high when they are in free water, low when they are immobilized in extracellular matrix) and this influences especially the transverse (T2) relaxation time, due to interactions with neighboring protons. In MRI sequences highlighting T2 (referred to as T2-weighted [W]), mobile water protons (such as in synovial fluid, or in tissue with increased free water content) give a hypersignal (long T2) whereas water protons immobilized in extracellular matrix (short T2) give a hyposignal. Since T2 reflects water content and integrity of the extracellular matrix, specialized T2 sequences have been created to identify early stages of degeneration of cartilage. Overall, T2 sequences are preferred to help identify pathology where changes in water content exist.

The term 'T2 time' or 'T2 relaxation time' refers to the measure of the time constant for the decay of transverse magnetization, T2. With T2 mapping, T2 relaxation times are transformed into a 2-dimensional, color map.

In order to visualize T2 measure, a color scale was used to identify variations in T2 time. We used the software Telemis. Blue color (high score) indicated areas of short T2 time and red color (low score) of long T2 time. Regions of Interest (ROIs) were placed in the middle area of the meniscus (**Fig.16**) after image processing in white and black to better distinguish meniscus. Coronal images were useful to observe the body of the meniscus (**Fig.15**).

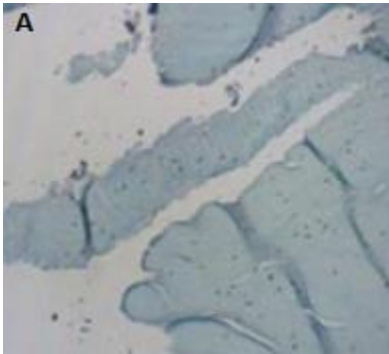

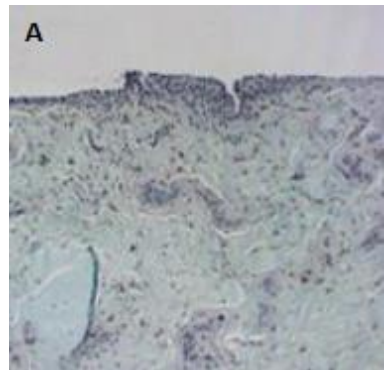
Table 2: Microscopic scoring of cartilage according to OARSI (Little et al, 2010). For each parameter, the lowest score (A) and the highest score (B) are represented.

Parameters		Score
<p style="text-align: center;">Structure</p> 	Normal (A)	0
	Slight surface irregularities (surface barely disturbed)	1
	Moderate surface irregularities (surface roughened)	2
	Severe surface irregularities (disruption, fissuring/fibrillation to < 10% depth)	3
	Fissures to transitional zone (1/3 depth)	4
	Fissures to radial zone (2/3 depth)	5
	Fissures to calcified zone (full depth)	6
	Erosion or severe fibrillation to mid zone (1/3 depth)	7
	Erosion or severe fibrillation to deep zone (2/3 depth)	8
	Erosion or severe fibrillation to calcified zone (full depth)	9
Erosion or severe fibrillation to subchondral bone (B)	10	
<p style="text-align: center;">Chondrocyte density</p> 	Normal (A)	0
	Increase or slight decrease	1
	Moderate decrease	2
	Severe decrease	3
	No cells (B)	4

<p style="text-align: center;">Cell cloning</p> 	Normal (A)	0
	Several doublets	1
	Many doublets	2
	Doublets and triplets	3
	Multiple cells tests or no cells in section (B)	4
<p style="text-align: center;">Interterritorial Toluidine Blue</p> 	Normal (A)	0
	Decreased staining to mid zone (1/3 depth)	1
	Decreased staining to deep zone (2/3 depth)	2
	Decreased staining to calcified zone (full depth)	3
	No staining (B)	4
<p style="text-align: center;">Tidemark-calcified cartilage-subchondral bone</p> 	Intact subchondral bone plate + single tidemark (A)	0
	Intact subchondral bone plate + duplicated tidemark	1
	Blood vessels penetrate through subchondral bone plate to calcified cartilage	2
	Tidemark penetrated by blood vessels (B)	3

% Surface area affected across the entire femoral or tibial condyle	No structural damage	0
	<10% surface area with structural damage extending below 10% depth	1
	10-25% surface area with structural damage extending below 10% depth	2
	26-50% surface area with structural damage extending below 10% depth	3
	51-75% surface area with structural damage extending below 10% depth	4
	> 75% surface area with structural damage extending below 10% depth	5

Table 3: Microscopic grading of meniscal changes (Cook et al, 2010). The highest score is represented for each parameter.

Parameters		Scores
Tissue Architecture – Tissue loss 	Normal	0
	Minimal disruption	1
	Moderate disruption with loss of tissue	2
	Complete loss of tissue architecture, >50% loss (A)	3
Cell and matrix (PG and Collagen) content and morphology 	Normal	0
	Minimal alterations in cell and matrix content and morphology	1
	Moderate alterations in cell and matrix content and morphology	2
	Severe loss/disruption of cells, PG, and collagen (A)	3
Proliferative response 	None	0
	Minimal proliferation of cells at synovial-meniscal junction	1
	Proliferation of cells at synovial junction and extending into tissue or along surfaces	2
	Marked proliferation of cells involving majority of remaining tissue (A)	3

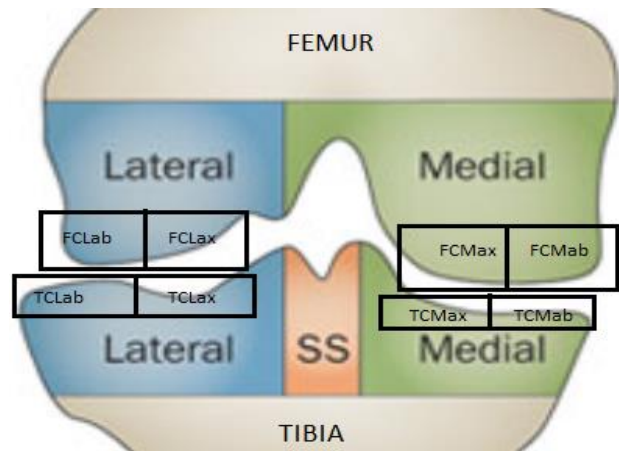


Figure 16: The anatomic sub-regions of articular cartilage (adapted from Guermazi et al, 2013). TCM, medial tibial condyle. TCL, lateral tibial condyle. FCM, medial femoral condyle. FCL, lateral femoral condyle. Ax, axialpart. Ab, abaxialpart.

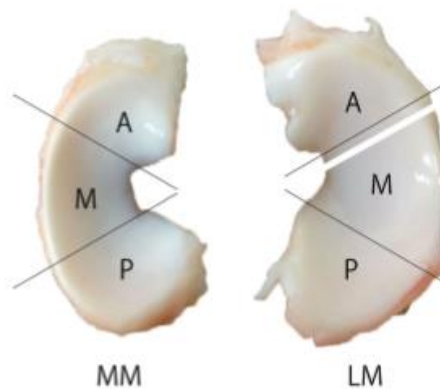


Figure 17: Meniscal division for histology assessment. Each meniscus was divided in three parts: Anterior (A), Middle (M) and Posterior (P). Two sections from middle part were used for evaluation (Zhang et al, 2014).

4.6.3 Gross anatomy

After euthanasia, stifles joints were disarticulated and soft tissue was removed from detached limbs.

4.6.4 Histology of cartilage

Three to four millimetre thick osteochondral slabs were cut in the median part of the MTC (medial tibial condyle), MFC (medial femoral condyle), LTC (lateral tibial condyle) and LFC (lateral femoral condyle) (**Fig. 16**). Samples were fixed in 10% (v/v) neutral buffered formalin for 48h. Following fixation, samples were transferred to 70% (v/v) ethanol for storage or further processing. They were decalcified in DC3 (nonionic surfactants, chlorhydric acid, EDTA) for 2 days and embedded in paraffin. Four-micron sections were cut. Sections were de-paraffinised with xylene and graded ethanol, and then stained with toluidine blue. Scoring for sheep recommended by OARSI was used to evaluate the cartilage. Two investigators who were blinded to the identity of the slices carried out histological analysis independently. When differences were present, results were discussed until a consensus was reached (**Table 2**).

4.6.5 Histology of menisci

Two sections from the middle part of each meniscus (lateral and medial) were cut for each knee (right and left) (**Fig.17**). Samples were fixed in 10% (v/v) neutral buffered formalin for 48h. Following fixation, samples were transferred to 70% (v/v) ethanol for storage or further processing. They were decalcified in DC3 (nonionic surfactants, chlorhydric acid, EDTA) for 2 days and embedded in paraffin. Four-micron sections were cut. Sections were de-paraffinised with xylene and graded ethanol, and then stained with toluidine blue. Histological analysis was carried out independently by two investigators who were blinded to the identity of the slices. When differences were present, results were discussed until a consensus was reached (**Table 3**).

Scoring was performed using the OARSI recommendations for histological evaluation of dog menisci in table 3 (Cook et al, 2010), since no validated scoring system is available for sheep. Histological abnormalities were assessed by looking at tissue architecture, cell and matrix content and proliferative response (**Table 3**).

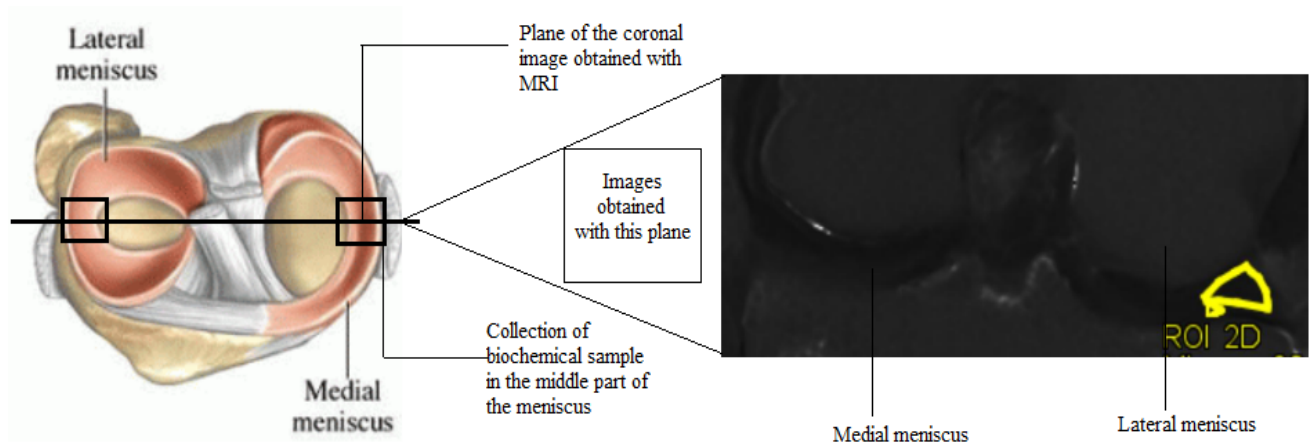


Figure 18: Identical areas between biochemical samples and T2 mapping images. For each meniscus, the middle part was cut in order to assay the biochemistry. This middle part correspond to the plane in which coronal images is obtained in the knee with MRI.

4.6.6 Biochemical assessment

Samples were collected from middle part of each meniscus in the region in which passes the plane of coronal images (**Fig.18**). Thereafter, they were stored at -80°C before analysis.

In the middle part of each menisci, a sample of 2-3 mm was cut with a scalpel blade. They were stocked at -80°C in Eppendorf's before manipulations.

Samples were weighted before and after freeze drying (AMSCO/Finn-AquaLyovacGT2, pressure=6.5x10⁻¹mbar, -25°C) to determine water content.

Samples were digested in papain (from papaya latex, Sigma®): the sample was mixed with 500µl of papain working solution (240µl of papain and 9.76ml of papain buffer 1X). The mix was incubated overnight at 60°C to allow the digestion of the tissue.

To measure the collagen content, the hydroxyproline (OH-Pro) assay was used (Bergman et Loxley, 1963; Edwards et O'Brien, 1980). In this technique, OH-Pro is oxidized by chloramine T and coupled with dimethylaminobenzaldehyde (DMBA) that result in coloration. 100 µL of papain were mixed with 200 µL of HCL 9M and the reaction was performed all the night at 110 °C in a sand bath. After dilution in a volume of 10 mL of distilled water, 1mL of the solution was poured in glass hydrolysis tubes, to which was added 1mL of diluent (solution 66% propanol : 100ml of propan-2-ol and 50ml of distilled water), and 1mL of an oxidant (0.42g chloroamine T, 5ml distilled water, and 25ml stock buffer composed of sodium acetate, trisodium citrate 2H₂O, citric acid, propan-2-ol and distilled water). 1ml of color reagent (3g DMBA, 4.5ml perchloric acid 70%, 25ml propan-2-ol) was added after 20 minutes. After 14 minutes, the tubes were heated in a water bath at 70°C for 20 minutes. The samples were left for 10 minutes before reading the absorbance. The measure of the coloration (between yellow and pink) was done at 550 nm in a 96-well ELISA microplate (U-bottom, Microlon®) with 200 µL of each treated sample. The standard curve from 0 µg/mL to 100 µg/mL was established with Trans-4-L-hydroxyproline (Sigma®). Each measure was done in triplicates. The mean was used to measure the OHPro content of each sample. Collagen content was calculated considering that collagen is made of 14% of OHPro. The collagen dry weight of each sample was calculated.

PG content was estimated by quantifying the amount of sulfated GAGs with a DMMB assay. After digestion in papain, 100 µL of each sample were diluted (1:100) in distilled water. 40µL of diluted sample were put in a 96-well Elisa microplate (U-bottom, Microlon®) with 250 µL dying agent (DMMB: 16mg of 1-9 dimethylmethylene blue, 2g of sodium formate, 2ml of formic acid in 1 liter of water). The absorbance was read at 620 nm with a spectrophotometer (Multiskan EX, Thermo Electron corporation). The standard curve from 0 µg/mL to 100 µg/mL was prepared with chondroitine-4-sulfate sodium salt from shark cartilage (Sigma®). Each measure was done in triplicates. The mean was used to accurately measure the GAG dry weight of each sample.

4.6.7 Statistical analysis

Data were collected in Microsoft Excel and analyses were performed using IBM® SPSS® Statistics, version 21.0. Shapiro-Wilk tests were used to examine the normality of data. Dependent data (right limb versus left limb/ TH group versus saline group) were compared by paired T-test for normal distribution (scores histology cartilage and total histology score of menisci) or paired Wilcoxon test for abnormal distribution (histological sub-scores of menisci). Spearman correlation test was used to evaluate if there is a correlation between biochemistry content (collagen, PGs and water) and T2 mapping values. A p-value less than 0.05 was considered to indicate a statistically significant difference.

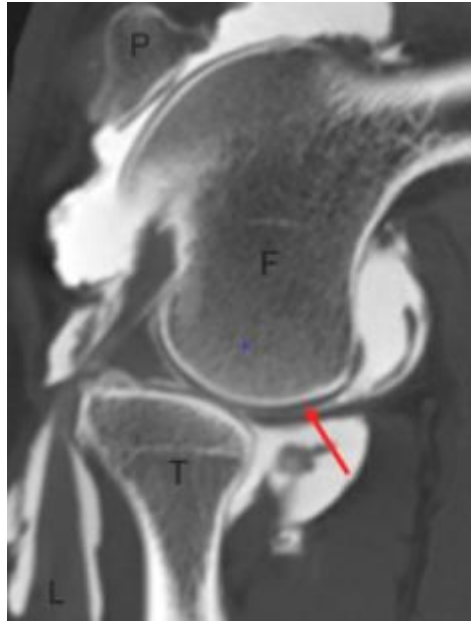


Figure 19: Sagittal images of cartilage obtained with CTA. This image represents a score 0. The white layer is the contrast while black layer (show with red arrow) is the cartilage.

Table 4: Table of the study population. S: Saline injection; TH: Triamcinolone Hexacetonide injection; y: year, m: month

Sheep	Injection		Age
	Right	Left	
1784	S	TH	4y8m
3262	TH	S	3y9m
3420	TH	S	3y9m
4656	S	H	5y11m
4864	TH	S	6y11m
5679	TH	S	6y8m
7234	TH	S	2y
7735	TH	S	10y10m
8239	S	TH	8y
8355	S	TH	10y1m
8565	TH	S	10y7m
8613	S	TH	10y6m
9076	S	TH	5y
7706	TH	S	2y4m
4872	TH	S	8y
7585	S	TH	2y7m
7680	S	TH	9y8m
5694	TH	S	7y7m

V. Results

5.0 Study population

18 sheep were recruited in study. Their ages ranged from 2 years to 10 years and 10 months. Right knee or left knee of each sheep were distributed randomly in TH or saline group (Table 4).

5.1 Computed tomography arthrography (CTA)

CTA was performed before injection in order to know if the cartilage was comparable at the baseline. Figure 19 shows a cartilage in perfect state in CTA (Fig.19). A score was attributed following the gravity of lesions observed. No score was higher than 2, the condition for their eligibility. No statistical difference in CTA scores was seen between knees.

5.2 Histology of cartilage

Among 144 histological slices of cartilage, 12 slices couldn't be analyzed due to artefacts, 5 slices in the saline group and 7 in the TH group. Significant difference was found in total histological score between TH group and saline group ($p = 0.004$).

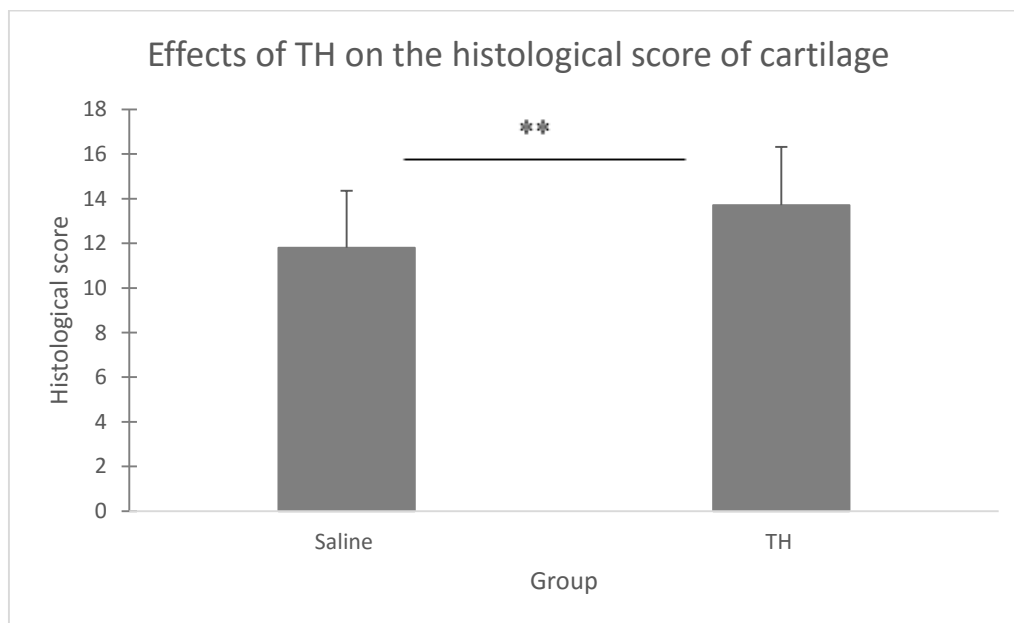


Figure 20: Effects of TH on the histological score of cartilage. Mean value for each group (n=18): 11.80 ± 1.96 (saline); 13.7 ± 2.21 (TH). Significant difference between the two groups ($p=0,004$). **p value < 0.01

The effect of TH on each histological sub-scores (structure, chondrocyte density, cell cloning, inter-territorial toluidine, tidemark-calcified cartilage-subchondral bone and extent of lesion) was calculated. No significant difference was found for structure ($p=0.222$), cell cloning ($p=0.379$), tidemark-calcified cartilage-subchondral bone ($p=0.775$) and extent of lesion ($p=0.088$) between group of saline and group of TH. However, a significant difference was found between group of saline and group of TH for chondrocyte density ($p=0.006$) and inter-territorial toluidine blue ($p=0.001$). For chondrocyte density and toluidine blue staining, scores were more important in the TH group, indicating a deleterious effect.

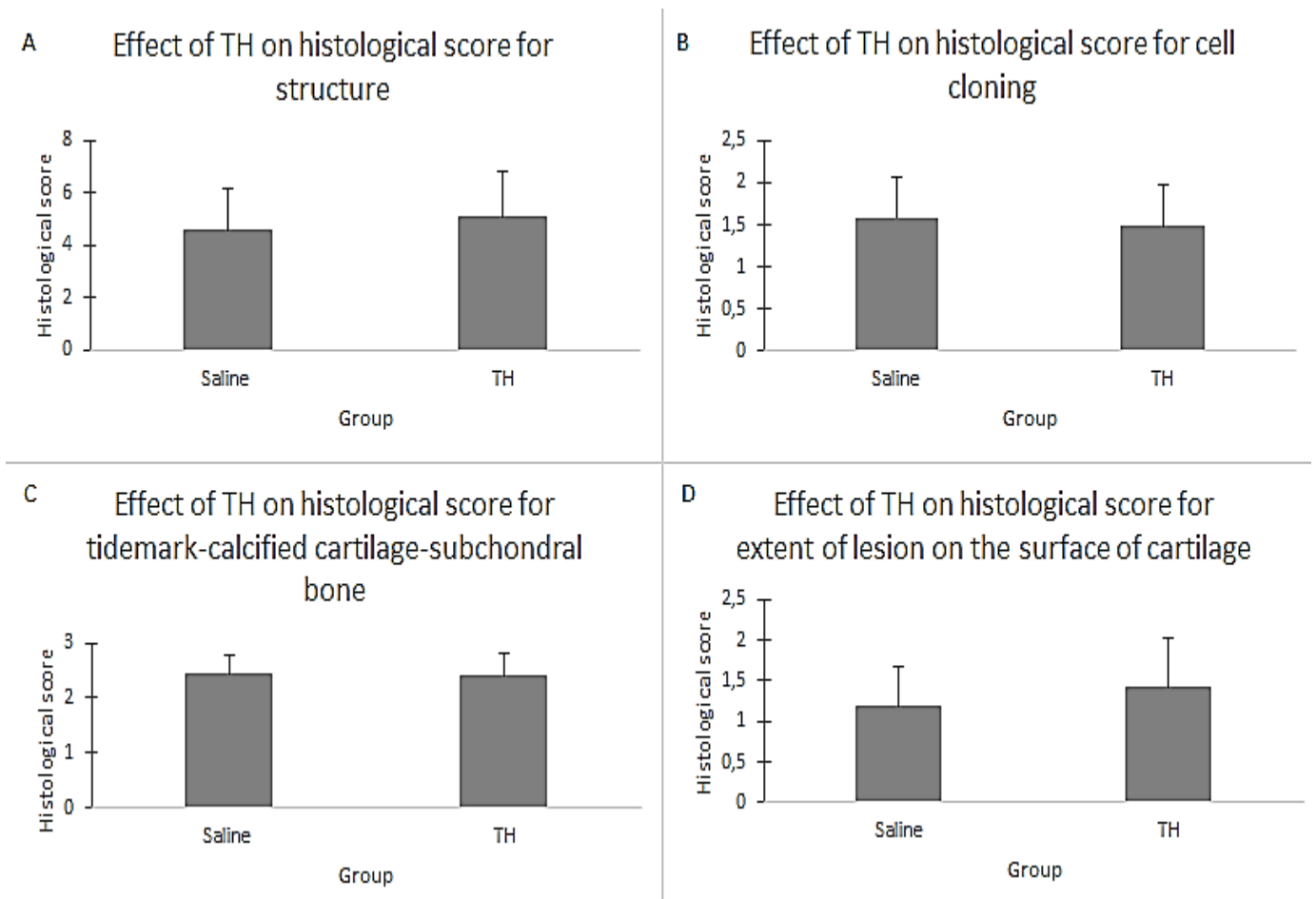


Figure 21: Effects of TH on histological sub-scores. A : structure (n=18) ; mean value: 4.59 ± 1.54 (saline group); 5.06 ± 1.77 (TH group), B: cell cloning (n=18); mean value: 1.58 ± 0.48 (saline group); 1.48 ± 0.49 (TH group), C: tidemark-calcified cartilage-subchondral bone (n=18); mean value: 2.43 ± 0.35 (saline group); 2.39 ± 0.41 (TH group), D: extent of lesion (n=18); mean value: 1.18 ± 0.50 (saline group); 1.41 ± 0.61 (TH group). No significant difference in these histological sub-scores for cartilage.

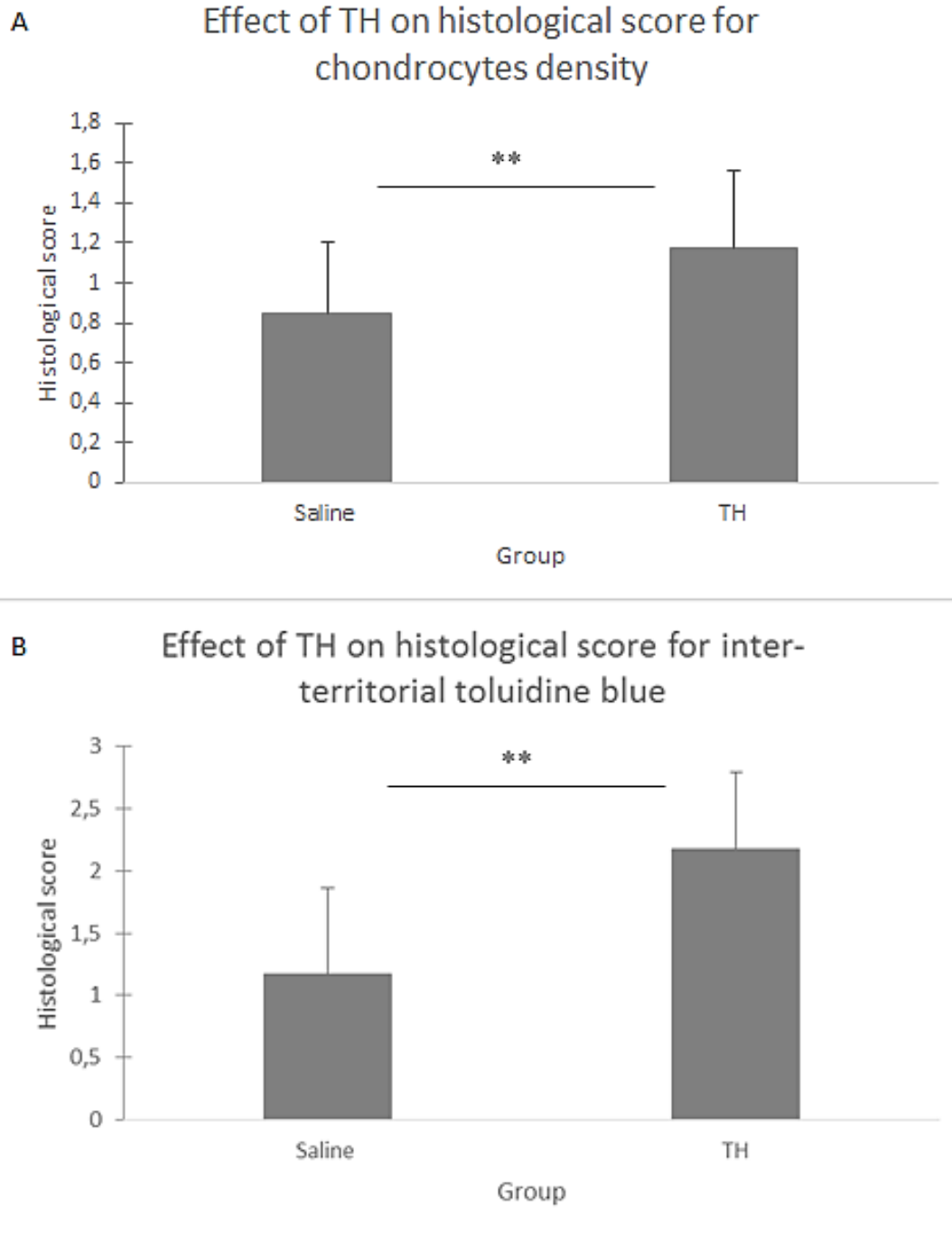


Figure 22: Effects of TH on histological sub-scores. A: chondrocyte density (n=18); mean value: 0.84 ± 0.37 (saline group); 1.18 ± 0.39 (TH group); significant difference between saline and TH group ($p=0.006$), B: inter-territorial toluidine blue (n=18); mean value: 1.17 ± 0.69 (saline group); 2.18 ± 0.62 (TH group). Significant difference between saline and TH group ($p=0.001$). ** p value < 0.01

Significant differences were found between tibial cartilage of the saline group and TH group ($p=0.002$) and between tibia and femur of TH group ($p=0.010$). Statistical analysis showed that no significant differences exist between tibia and femur in saline group ($p=0.895$) and between femur in the two groups (saline and TH) ($p=0.3521$). For one sheep, data were not sufficient to make comparison ($n=17$). The tibial cartilage in the TH group is the more affected.

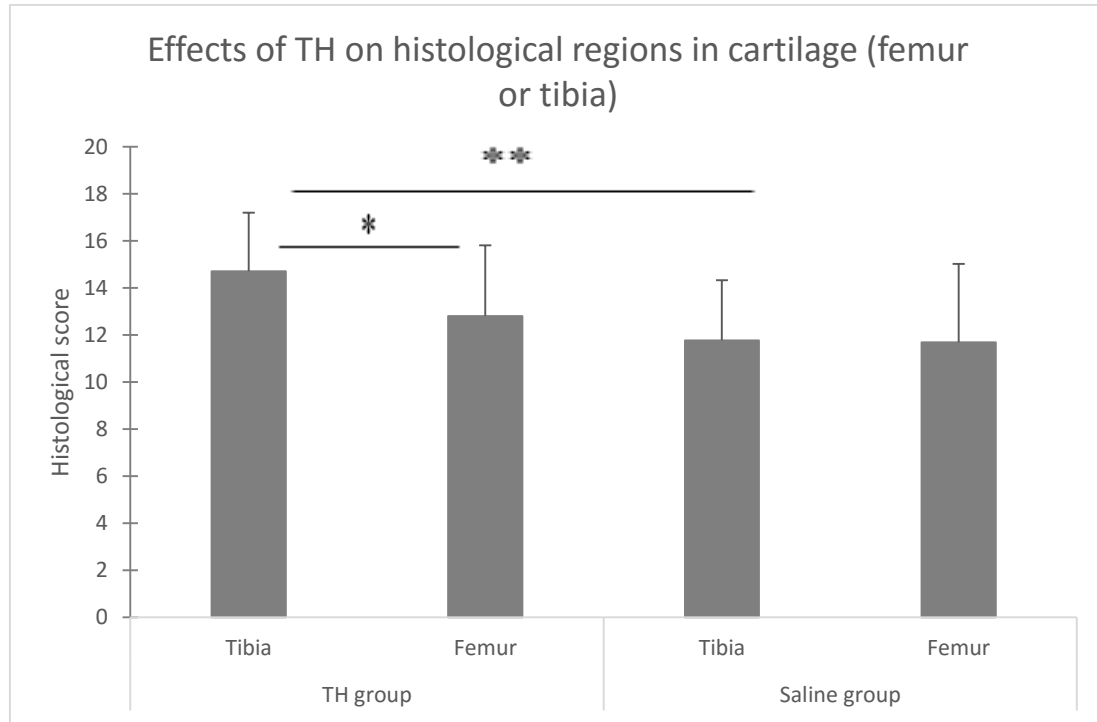


Figure 23: Effects of TH on histological regions in cartilage. Tibia in TH group ($n=17$); mean value: 14.70 ± 2.50 , Femur in TH group ($n=17$); mean value: 12.94 ± 3.00 , Tibia in saline group ($n=17$); mean value: 11.88 ± 2.55 , Femur in saline group ($n=17$); mean value: 12.00 ± 3.33 . Significant difference between tibia in TH group and tibia in Saline group ($p=0.002$). Another significant difference between tibia and femur of TH group ($p=0.010$) ** p value < 0.01 , * p value < 0.05

5.3 Histology of menisci

For the histology of menisci, 58 slices were assessed ($n=15$). For two sheep, one of the four slices (right lateral meniscus, right medial meniscus, left lateral meniscus, left medial meniscus) was missing due to artefacts. First, the difference between lateral or medial menisci following groups (saline or TH) was compared. No significant difference was found between lateral menisci of TH group and lateral menisci of saline group ($p=0.268$). In the same way, no significant difference was found between medial menisci of saline group and medial menisci of TH group ($p=0.665$). Contrariwise, medial menisci had a higher score than lateral menisci in the TH group but the difference was not significant ($p=0.063$). For the saline group, the difference between medial menisci and lateral menisci was significant ($p=0.033$).

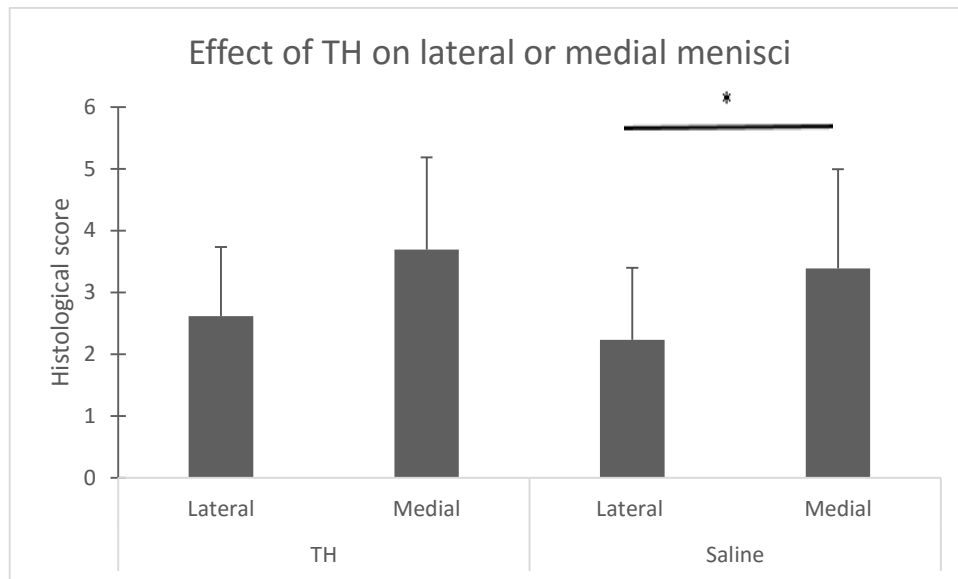


Figure 24: Effect of TH on lateral or medial menisci. Lateral menisci in TH group (n=13); mean value: 2.61 ± 1.12 , medial menisci in TH group (n=13); mean value: 3.69 ± 1.49 , lateral menisci in saline group (n=13); mean value: 2.23 ± 1.17 , medial menisci in saline group (n=13): 3.38 ± 1.61 . No significant difference was found except between lateral and medial menisci in the saline group (p=0.033). The difference between the medial and lateral meniscus in TH group is almost significant (p=0.063). * p value < 0.05

The total score between lateral and medial menisci in each group was realized and no significant difference was found between saline and TH group (p=0.410).

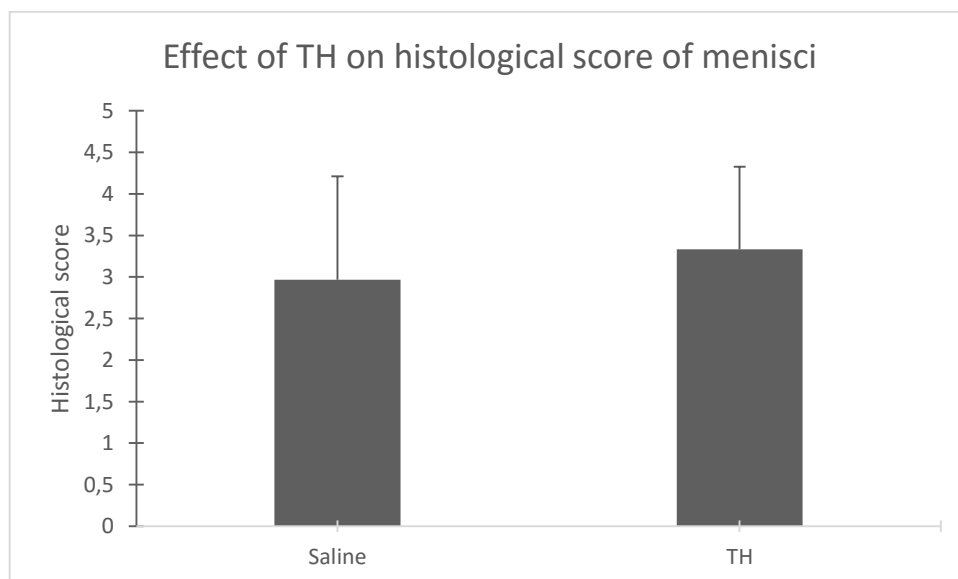


Figure 25: Effect of TH on histological score of menisci. Saline group (n=15); mean value: 2.97 ± 1.25 , TH group (n=15): 3.33 ± 0.99 . No significant difference between saline and TH group (p=0.410).

Each sub scores (matrix, tissue architecture and cells proliferation) were analyzed according to the group. A significant difference was found for the sub-score of cells proliferation (p=0.038).

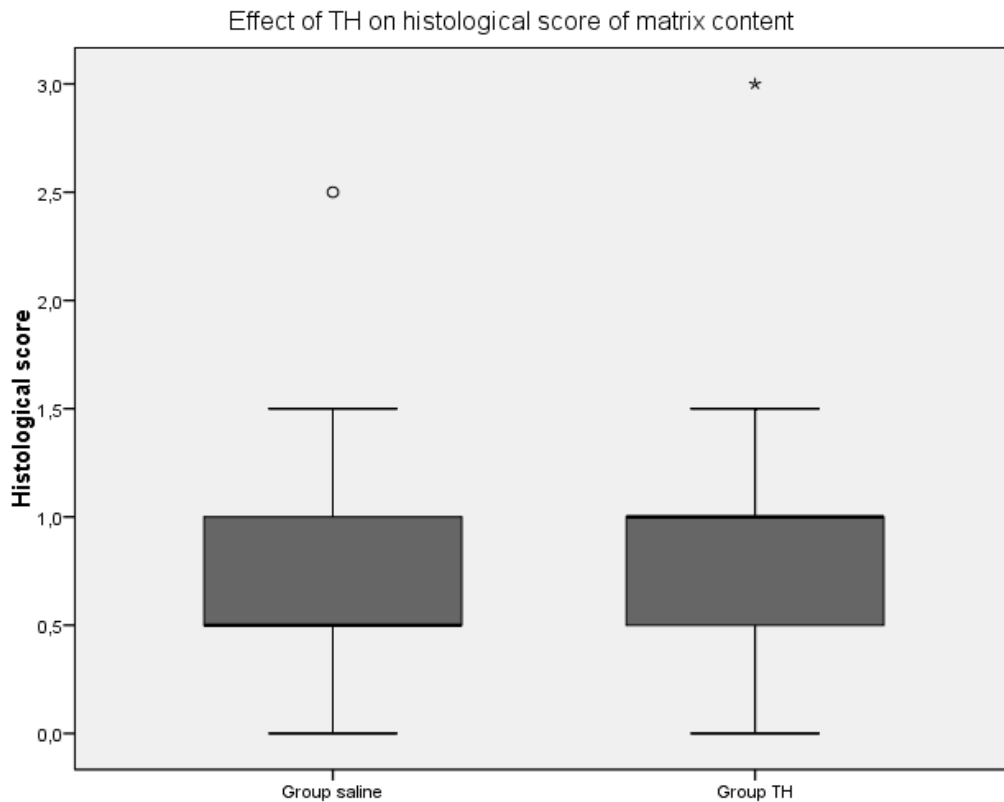


Figure 26: Effect of TH on histological score of matrix content. Group saline (n=15); median: 0.5, Group TH (n=15); median: 1. No significant difference between the two groups (saline and TH) ($p=0.381$).

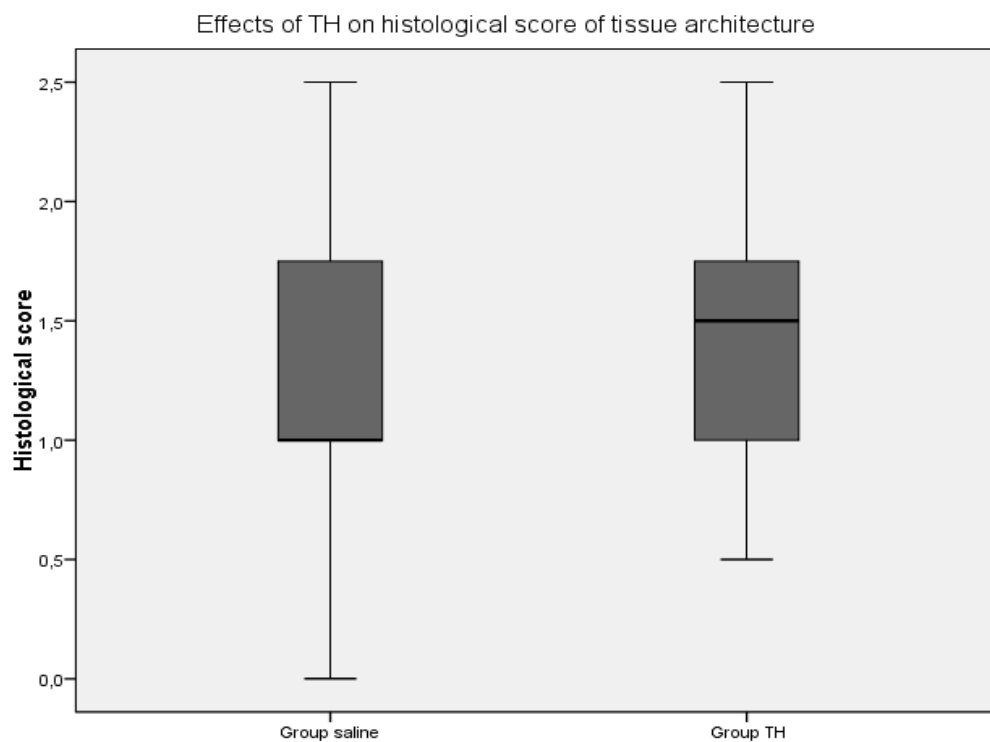


Figure 27: Effects of TH on histological score of tissue architecture. Group saline (n=15); median: 1, Group TH (n=15); median: 1.5. No significant difference between the two groups (Saline and TH) ($p=0.142$).

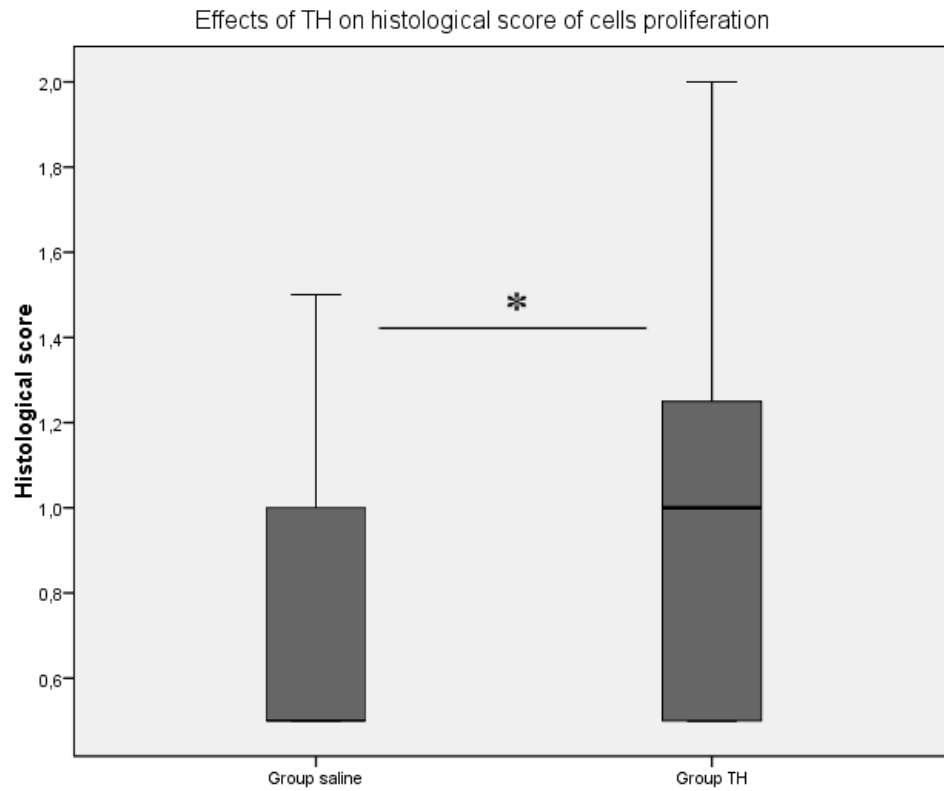


Figure 28: Effects of TH on histological score of cells proliferation. Group saline (n=15); median: 0.5, Group TH (n=15); median: 1. Significant difference between the two groups ($p=0.038$). * p value < 0.05

5.4 T2 mapping assessment

Three sheep (5 knee joints, 10 menisci) were assessed before and after injection. One knee could not be analyzed due to artefacts in images. No significant differences were found in T2 mapping between before and after saline injection ($p=0.728$) or TH injection ($p=0.449$).

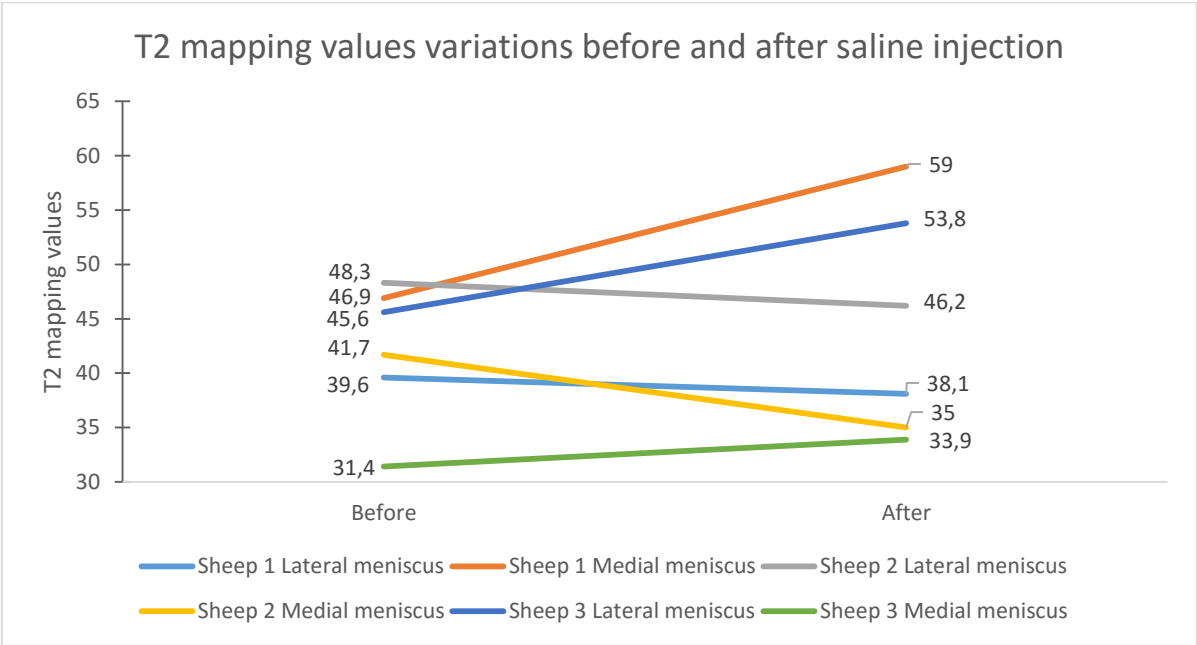


Figure 29: T2 mapping values variations before and after saline injection. Before injection ($p=6$); mean value: 42.25 ± 6.24 , After injection ($p=6$); mean value: 44.33 ± 10.42 . No significant difference between before and after saline injection in these three sheep ($p=0.728$).

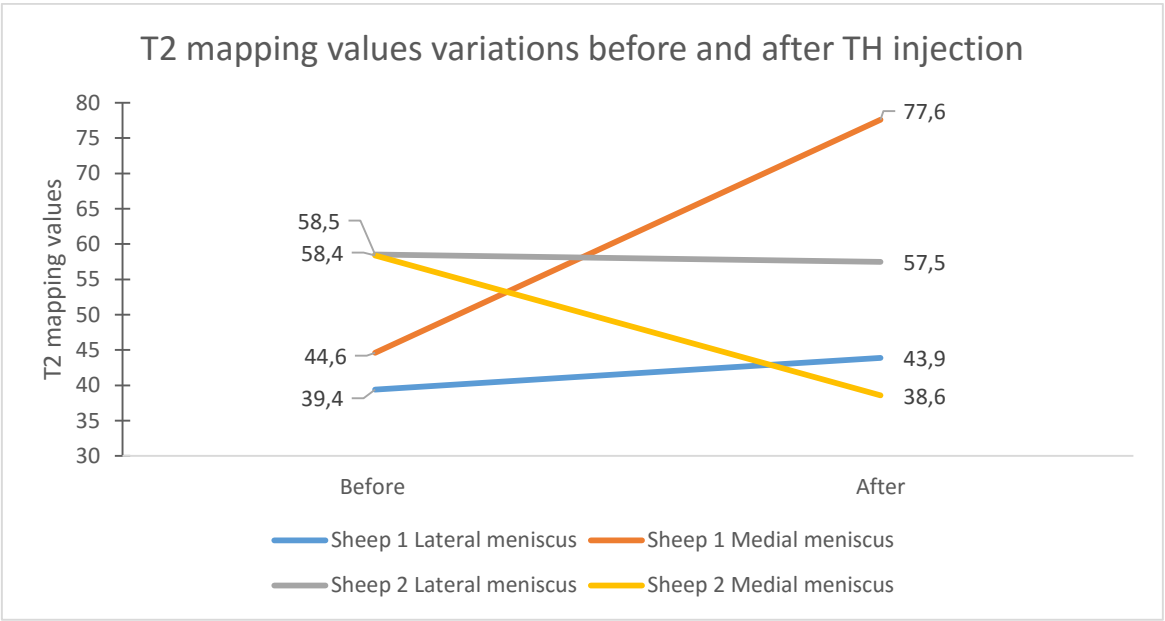


Figure 30: T2 mapping variation before and after TH injection. Before injection ($p=4$); mean value: 50.23 ± 9.73 , After injection ($p=4$); mean value: 54.40 ± 17.39 . No significant difference between before and after TH injection in these two sheep ($p=0.499$).

A correlation between each biochemical components (water, collagen and water) and T2 mapping values was realized. No significant correlation was found between each element of ECM and T2 mapping values (water: $p=0.239$, collagen: $p=0.724$, GAGs: $p=0.445$)

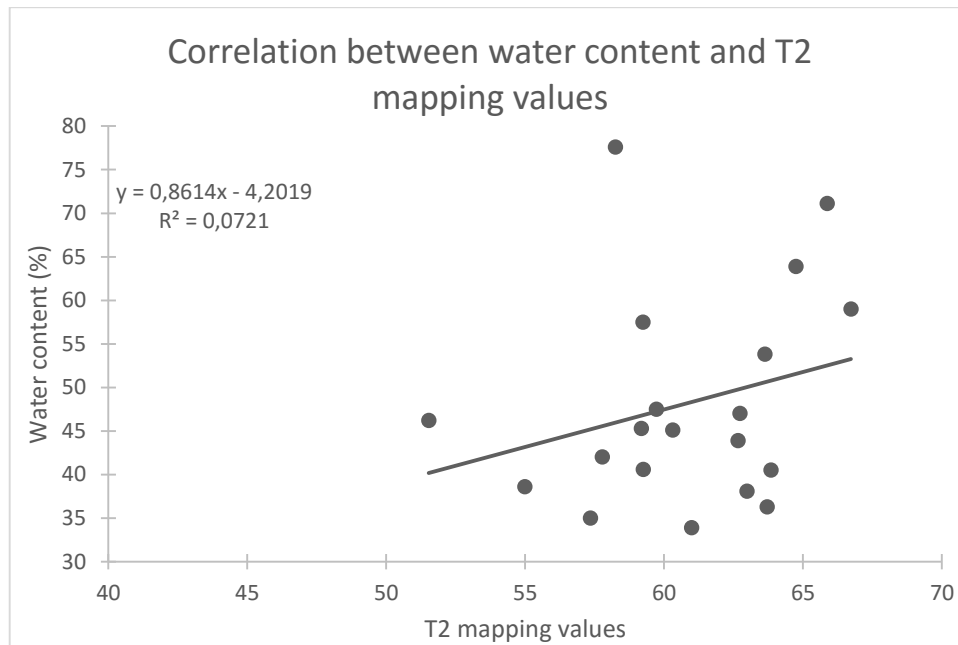


Figure 31: Correlation between water content and T2 mapping values. No significant correlation between the two variables ($p=0.239$).

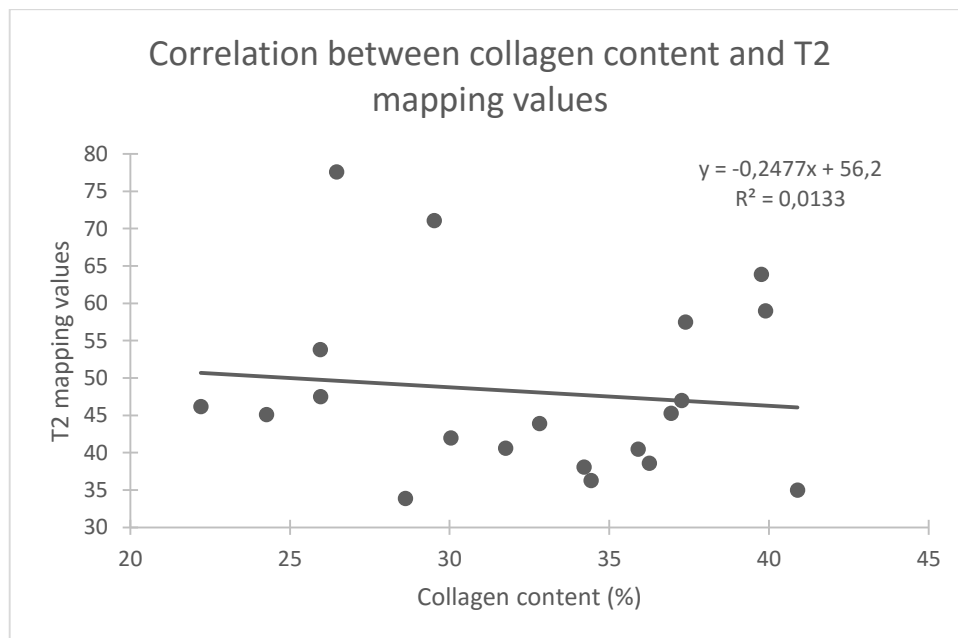


Figure 32: Correlation between dry collagen content (%) and T2 mapping values. No significant correlation between the two variables ($p=0.724$)

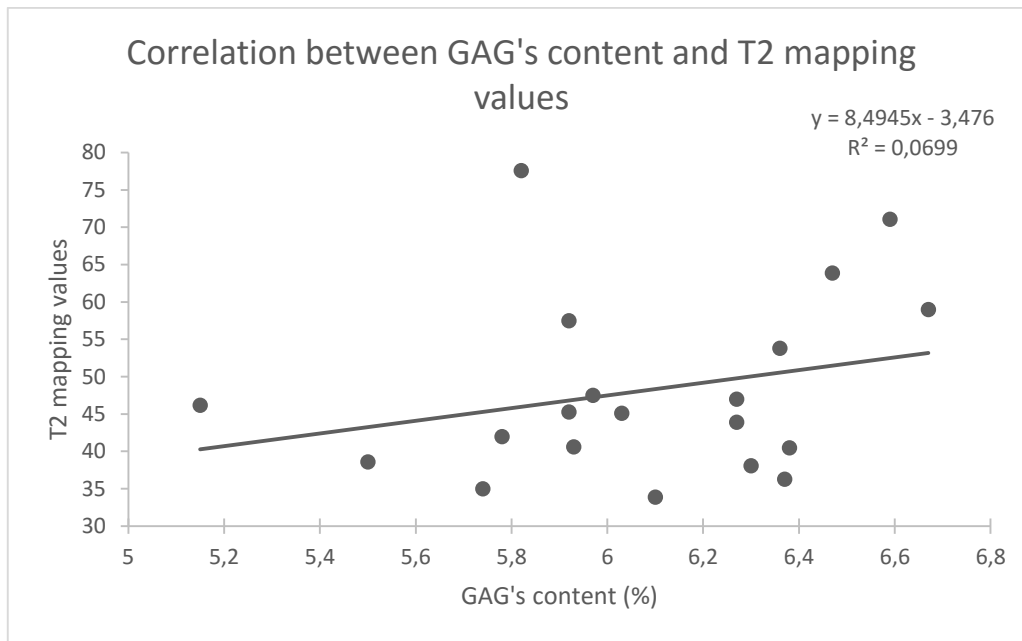


Figure 33: Correlation between dry GAG's content and T2 mapping values. No significant correlation between the two variables ($p=0.445$).

VI. Discussion

The first interesting finding in this study is the significant decrease of PGs in cartilage after injection of TH. The histology of cartilage in sheep showed a significant decrease in toluidine blue staining intensity. This staining decrease indicates a decrease in PG and GAG content (**Fig. 22**).

One study in vitro on equine chondrocytes showed that there is a decrease in PGs content after injection of CS (Byron et al, 2008). The same observation was made on cartilage explants of horses (Doyle et al, 2005). An in vitro study on human chondrocytes showed that CS inhibit synthesis of GAGs. (Hauser, 2010). An in vivo study on horses was also realized and reported that the content in PGs decreased after treatment (Chunekamrai et al, 1989). The effect of TH enhanced loss or inhibit synthesis of PGs in horses (Celeste et al, 2005).

In some studies, contrary wise, the PG content increased after injection of CS. It was the case in a study in horses that showed an increase in GAG content and synthesis in cartilage. In this study, an injection of 12 mg of TA was performed (Frisbie et al, 1997). In our study, the dose administered was 25 mg. Many studies show that CS have a time and dose-dependent impact on cartilage. Lower doses could have a positive effect while higher doses could have a deleterious effect (Wernecke et al, 2015).

The results obtained by histology in the current study have been confirmed by biochemistry (dimethylmethylene blue assay) for 13 sheep in another study (Yang, unpublished data). The dry content was 10.26 ± 2.67 % for saline group and 5.96 ± 3.32 % for TH group. There was a decrease in GAG content and therefore certainly in PG content.

This loss in PG in cartilage could be explained by the activation of p38 MAPK pathway via phosphorylation that modulates matrix protein transcription (Takebe et al, 2011). CS seem also to have directly an action on Golgi apparatus and inhibit synthesis of protein (Theranzadedsh et al, 2005). Different aggrecanases of the protease's family "A Disintegrin And Metalloproteinase with ThromboSpondin motifs' (ADAMTS) could also play a role in the degradation of aggrecan, one of the most important PG in cartilage (Huang et Wu, 2008). A study in-vitro in equine chondrocytes showed that activity of ADAMTS5 is more important in presence of CS (Busshers et al, 2010).

A significant increase in the histological score of chondrocyte density was observed in group injected with TH. This indicates a decrease of chondrocytes density inside the cartilage of knee joint injected with TH (**Fig.22**). Some studies in vitro indicate that CS could have a toxic effect on chondrocytes (Nakazawa et al, 2002; Studer et al, 2004). CS could block the anti-apoptotic effect of insulin-like growth factor (IGF-1) and lead to a premature cell death of chondrocytes (Hauser, 2010). The consequence in cells density is dependent of the time and the concentration of exposure. Indeed, short-term CS treatment induces an upregulation in chondrocytes autophagy, an adaptative mechanism to avoid chondrocyte death (Liu et al, 2014). In this study, 4 weeks seemed enough to have a deleterious effect on chondrocyte density.

Other histological sub-scores did not vary significantly difference between TH group and saline group. Injection of TH did not modify the number of chondrocytes clusters (**Fig.21**). In particular no modification of structure (such as fibrillation or fissures) was identified between the two groups (**Fig.21**). This is quite understandable since they are more advanced changes in the course of OA. Such advanced pathologic observations have been realized on animal studies which injection of CS was associated with running (Hauser, 2010).

The dissociation of histological scores obtained for tibia from those obtained for femur in each group (saline and TH) showed only a significant difference between tibial cartilage of the TH group and tibial cartilage of saline group (**Fig.23**). The anatomical location has an impact on the effect of TH. That could be explained by the fact that loading is more important for tibial plateau and in particular the medial tibial plateau that supports approximately 75% of load in sheep (Taylor et al, 2011).

About menisci, no significant difference in the total histological score or structural and matrix sub-scores was found between knees injected with TH or saline solution (**Fig.25/Fig.26/Fig.27**). At present, only few studies have tried to understand the impact of CS on menisci. With regard to the content in PG, a decrease was observed in menisci of rabbits while no difference was present in our study (Ishikawa et al, 1981). This result could be explained by some difference between studies. The first is the number of injections. In our study only one injection was realized while in the study of Ishikawa multiple injections were performed. The number of injection is described as having a deleterious impact on cartilage structure (Douglas, 2012). Moreover, menisci were removed after 2 months in rabbits. In this study, sheep were already euthanized after 4 weeks. The time of CS action was not identical for the two studies. In Ishikawa study, the prednisolone acetate was injected and the PK PD (its mode of action and transformation in the knee) is not the same as TH. Therefore, the comparison of results is difficult. In this study, the content of PG in menisci seemed to be more protected than in articular cartilage after injection of TH.

The only significant difference in histology sub-scores of menisci was for cells proliferation at meniscal-synovial junction (**Fig.28**). It means that there were more proliferative cells at meniscal-synovial junction in TH injected knee, indicating an increased activity. In the literature, the origin of these cells is not clear. It could be stem cells deriving from synovium (mesenchymal stem cells with high chondrogenic potential) or joint capsule (Nakagawa et al, 2015). Another hypothesis is that a signal is transmitted in presence of TH to cells of the superficial zone considered like progenitor cells and implicated in tissue homeostasis and repair (Van der Bracht et al, 2007). As the number of meniscal cells increase, PG content in menisci could be better renew than in articular cartilage. This would explain the little difference in PG content between TH group and saline group. Increased proliferation of cells can be seen as beneficial or as the other way round indicating an attempt to repair.

Interestingly, the histological score is more important for medial menisci compared to lateral menisci in the saline group and in the TH group (**Fig.24**). In this study, the medial menisci is more affected independently of the type of injection. In human, the prevalence of degenerative tears seems to be more important in the posterior and middle part of medial meniscus.

The more important histological scores in medial menisci could be explained by a higher probability of degeneration. However, no information about the natural occurring of meniscal tears in sheep is available (Larking, 2010).

The T2 mapping results were not correlated with biochemistry values. There was no significant correlation between water (**Fig.31**), collagen (**Fig.32**), PGs (**Fig.33**) and T2 mapping values. Actually, T2 mapping values on menisci are not fully understood and are based upon findings in articular cartilage (Zarins et al, 2010). One study on menisci demonstrated that T2 mapping relaxation time is strongly associated with water content but weakly with PG and collagen content from late-stage OA patients (Son et al, 2013). Another study found that this technique allowed differentiating menisci in different pathologic grades. In consequence, a better understanding of this technology in menisci could have implications for early detection of degeneration (Zarins et al, 2010). In this study, sample size was only of 5 animals and did not allow drawing definitive conclusions.

Moreover, T2 mapping values showed no significant difference between TH group and saline group (**Fig.29/Fig.30**). Artefacts or micro fissures inside the matrix could be the explanation of values variations. In the literature, no study was performed about the impact of CS on T2 mapping values in menisci. In the future, it will be interesting to study T2 mapping in an OA model and the impact of CS in this model.

Study limitations

The PK/PD of TH is not known in sheep. Thereby, the time after which the effect of TH is maximum, is not easy to define. 4 weeks was chosen because human data indicate a complete absorption of the drug 2-3 weeks after administration (Derendorf et al, 1986). This information should be specified in next studies.

The group control was assessed with injection of saline solution. The vehicle drug is composed of Liquid Sorbitol (E 420), polysorbate 80, benzyl alcohol, hydrochloric acid and water for injection. It will be useful to use this excipient in the control group in order to verify real impact of TH on menisci and cartilage. Unfortunately, the microcrystal structure of CS cannot be mimicked for the moment.

A review of studies using animal models of OA (horses, dogs and rabbits) has shown that a systemic effect is possible (Vandeweerd et al, 2015). Injection of CS in one joint can have effect on the contralateral joint even if it is not injected (Frisbie et al, 1997). A pure control without medication could be compared to detect contralateral effect of drug.

Another point to check in next studies is the possible side effect of CS on metabolism. A modification of the endogenous cortisol inside the animal could be compared with control group. CS could act on the hypothalamic-pituitary-adrenal axis and diminish the basal rate of cortisol (Habib et al, 2015). However, the risk of adverse effects is very weak with one injection.

VII. Perspectives and conclusions

In the current study, the most interesting finding was the decrease of PG in healthy knee joint of sheep injected with TH at the clinical doses (25 mg). The chondrocyte density was also affected by TH injection inside the cartilage. Moreover, the impact of TH was not identical in each region. The tibial cartilage independently of medial or lateral side was the most affected zone with TH injection in comparison to saline group.

About menisci, cells proliferation was more important in menisci of TH group. However, no difference was found in PG content. In the two groups, the histological scores of medial menisci are more important than lateral.

These data show that CS could have a deleterious impact on cartilage matrix at clinical dose (25 mg) while menisci seem to be more protected at the same dose.

In this study, histology was largely used. This technique allows collecting qualitative information on structural and matrix state of menisci and cartilage. Though all sections were read in double blinding, the results need to be verified with quantitative information. In order to evaluate ECM content such as biochemistry techniques.

In the future, it will be interesting to differentiate the different type of collagen (type 1, type 2, type 3, etc.) and PGs (aggrecan, biglycan, decorin, etc.). Specific ELISA could be a way to determinate different protein concentration.

Moreover, TH could influence the transcription level of some proteins. For example in OA meniscus, the transcription of pro-collagen is amplified (Katsuragawa et al, 2010). RTq-PCR is a technic which could be added in study to determine the effect of TH on RNA content (Vonk et al, 2009).

The strength of this study was the verification at baseline of cartilage and menisci with non-invasive technique like CTA. It was generally a lack in research studies. The two groups were formed with similar characteristics and no statistical differences in cartilage gross anatomy.

A technique of compositional imagery was also used in the study. T2 mapping values did not correlate with any biochemical elements. Moreover, no significant difference was found before and after injection of TH. However, the number of sheep (n=5) was not sufficient to draw conclusions. T2 mapping is maybe a technique more adapted to detect change in OA disease and need to be conducted in next studies.

In order to know the effect of CS in an OA disease, a model in sheep need to be developed. Meniscectomy (removal of one of the two menisci) allows destabilizing the distribution of force inside the knee and leading to OA onset. This model will be interesting to study the effect of TH at 25 mg in OA knee joints.

Some studies suggest that low doses could have a chondroprotective effect in cartilage. Other studies with low doses of TH (5 mg) will be realized in future. The comparison between low doses (5 mg) and clinical doses (25 mg) could be performed to know the effect of TH on healthy knee joint and OA knee joint.

VIII. Remerciements

Tout d'abord, je voudrais remercier Nathalie Kirshvinck de m'avoir accueilli durant une année dans l'unité de recherche vétérinaire intégrée (URVI).

Ensuite, merci à mon promoteur Jean-Michel Vandeweerd de m'avoir intégré dans ses recherches sur l'ostéoarthrite et de m'avoir supervisé pour mon mémoire.

Merci également à Laetitia, Isabelle et Damien pour leur bonne humeur, leur aide et leur conseil.

Un grand merci à Vincent et Hélène d'avoir passé leur samedi avant-midi (et parfois plus) et leur soirée à nous aider que ce soit à Mont-Godinne pour les imageries ou à la Rue Muzet pour les dissections. Votre aide a été précieuse !

Je n'oublie pas non plus de saluer toute l'équipe de Mont-Godinne et plus particulièrement Jean-François Nisolle sans qui toutes les imageries ne seraient pas réalisables.

J'en profite aussi pour dire merci au docteur Cécile Abraham de m'avoir accordé de son temps pour m'aider dans la lecture des T2 mapping.

Je tiens aussi à remercier Mireille pour son aide lors des expériences de zymographie et plus globalement à l'unité de pharmacologie, pharmacothérapie et toxicologie du professeur Pascal Gustin. C'est également l'occasion de remercier Joelle Piret et Nadine Antoine pour l'aide en histologie.

Merci également à Marianne Raes de m'avoir accueilli dans son bureau pendant 10 mois.

C'est aussi l'occasion de remercier mes parents pour leur énorme soutien pendant le mémoire mais également depuis de nombreuses années.

J'en profite aussi pour saluer ma famille et mes amis qui ont toujours cru en moi.

Je n'oublie pas non plus Giulia, ma co-mémorante, qui a dû me supporter pendant 10 mois.

Et puis le mémoire c'est également de belles rencontres de l'autre côté de la planète. Merci à toi Yang.

Pour finir, je remercie les membres du jury pour la lecture de mon mémoire.

IX References

- Alshami AM. Knee osteoarthritis related pain: a narrative review of diagnosis and treatment. *Int J Health Sci.* 2014; 8: 85-104
- Amiri S, Cooke D, Kim IY, Wyss U. Mechanics of the passive knee joint. Part 1: The role of the tibial articular surfaces in guiding the passive motion. *Proc Inst Mech Eng H.* 2006; 220: 813-822
- Arnockzky SP, Warren RF, Spivak JM. Meniscal repair using an exogenous fibrin clot. An experimental study in dogs. *J Bone Joint Surg Am.* 1988; 70: 1209-1217
- Attur M, Al-Mussawir HE, Patel J, Kitay A, Dave M, Palmer G, Pillinger MH, Abramson SB. Prostaglandin E2 exerts catabolic effects in osteoarthritis cartilage: evidence for signaling via the EP4 receptor. *J Immunol.* 2008; 181: 5082-5088
- Ayhan E, Kesmezacar H, Akgun I. Intraarticular injections (corticosteroid, hyaluronic acid, platelet rich plasma) for the knee osteoarthritis. *World J Orthop.* 2014; 18: 351-361
- Baker BE, Peckham AC, Puppato F, Sanborn JC. Review of meniscal injury and associated sports. *Am J Sports Med.* 1985; 13: 1-4
- Bannuru RR, Natov NS, Obadan IE, Price LL, Schmid CH, McAlindon TE. Therapeutic trajectory of hyaluronic acid versus corticosteroids in the treatment of knee osteoarthritis: a systematic review and meta-analysis. *Arthritis Rheum.* 2009; 61: 1704-1711
- Bannuru RR, Schmid CH, Kent DM, Vaysbrot EE, Wong JB, McAlindon TE. Comparative effectiveness of pharmacologic interventions for knee osteoarthritis: a systematic review and network meta-analysis. *Ann Intern Med.* 2015; 162: 46-54
- Baum T, Joseph GB, Karampinos DC, Jungmann PM, Link TM, Bauer JS. Cartilage and meniscal T2 relaxation time as non-invasive biomarker for knee osteoarthritis and cartilage repair procedures. *Osteoarthr Cartilage.* 2013; 21: 1474-1484
- Beaufils P, Verdonck R. *The meniscus.* Springer. 2010; 11-155
- Berenbaum F. Osteoarthritis as an inflammatory disease. *Osteoarthr Cartilage.* 2013, 21: 16-21
- Bergman I, Loxley R. Two improved and Simplified Methods for the Spectrophotometric Determination of Hydroxyproline. *Anal Chem.* 1963; 35: 1961-1965
- Bijlsma JW, Berenbaum F, Lafeber FP. Osteoarthritis : an update with relevance for clinical practice. *Lancet.* 2011; 377: 2115-2126
- Blalock D, Miller A, Tilley M, Wang J. Joint instability and osteoarthritis. *Clin Med Insights Arthritis Musculoskelet Disord.* 2015; 8: 15-23
- Braun HJ, Gold GE. Diagnosis of Osteoarthritis: Imaging. *Bone.* 2012; 51: 278-288

- Busschers E1, Holt JP, Richardson DW. Effects of glucocorticoids and interleukin-1 beta on expression and activity of aggrecanases in equine chondrocytes. *Am J Vet Res.* 2010; 71: 176-185
- Byron CR, Benson BM, Stewart AA, Pondenis HC. Effects of methylprednisolone acetate and glucosamine on proteoglycan production by equine chondrocytes in vitro. *Am J Vet Res.* 2008; 69: 1123-1128
- Cake MA, Smith MM, Young AA, Smith SM, Ghosh P, Read RA. Synovial pathology in an ovine model of osteoarthritis: effect of intraarticular hyaluronan (Hyalgan). *Clin Exp Rheumatol.* 2008, 26: 561-567
- Caron JP. Intra-articular injections for joint disease in horses. *Vet Clin N Am-Equine.* 2005; 21: 559-573
- Céleste C, Ionescu M, Robin Poole A, Laverty S. Repeated intraarticular injections of triamcinolone acetonide alter cartilage matrix metabolism measured by biomarkers in synovial fluid. *J Orthop Res.* 2005; 23: 602-610
- Chang A, Moisio K, Chmiel JS, Eckstein F, Guermazi A, Almagor O, Cahue S, Wirth W, Prasad P, Sharma L. Subregional effects of meniscal tears on cartilage loss over 2 years in knee osteoarthritis. *Ann Rheum Dis.* 2011; 70: 74-79
- Chu SC, Yang SF, Lue KH, Hsieh YS, Li TJ, Lu KH. Naproxen, meloxicam and methylprednisolone inhibit urokinase plasminogen activator and inhibitor and gelatinases expression during the early stage of osteoarthritis. *Clin Chim Acta.* 2008; 387: 90-96
- Chunekamrai S, Krook LP, Lust G, Maylin GA. Changes in articular cartilage after intra-articular injections of methylprednisolone acetate in horses. *Am J Vet Res.* 1989; 50: 1733-1741
- Cook JL, Kuroki K, Visco D, Pelletier JP, Schulz L, Lafeber FP. The OARSI histopathology initiative – recommendations for histological assessments of osteoarthritis in the dog. *Osteoarthr Cartilage.* 2010; 18: 66-79
- Derendorf H, Möllmann H, Grüner A, Haack D, Gyselby G. Pharmacokinetics and pharmacodynamics of glucocorticoid suspensions after intra-articular administration. *Clin Pharmacol Ther.* 1986; 39: 313-317
- Douglas RJ. Corticosteroid injection into the osteoarthritic knee: drug selection, dose, and injection frequency. *Int J Clin Pract.* 2012; 66: 699-704
- Dowd G, Gaynor JS, Alvis M. A comparison of transdermal fentanyl and oral phenylbutazone for post-operative analgesia in sheep. *Vet Surg.* 1998; 26: 168
- Doyle AJ, Stewart AA, Constable PD, Eurell JA, Freeman DE, Griffon DJ. Effects of sodium hyaluronate and methylprednisolone acetate on proteoglycan synthesis in equine articular cartilage explants. *Am J Vet Res.* 2005; 66: 48-53

Edwards CA, O'Brien WD. Modified assay for determination of hydroxyproline in a tissue hydrolyzate. *Clinica Chemica Acta*. 1980; 104: 161-167

Englund M, Guermazi A, Lohmander SL. The role of the meniscus in knee osteoarthritis: a cause or consequence? *Radiol. Clin. North. Am.* 2009; 47: 703-712

Englund M, Niu J, Guermazi A, Roemer FW, Hunter DJ, Lynch JA, Lewis CE, Torner J, Nevitt MC, Zhang YQ, Felson DT. Effect of meniscal damage on the development of frequent knee pain, aching, or stiffness. *Arthritis Rheum.* 2007, 56: 4048-4054

Englund M, Roemer FW, Hayashi D, Crema MD, Guemarzi A. Meniscus pathology, osteoarthritis and the treatment controversy. *Nat. Rev. Rheumatol.* 2012; 8: 412-419

Felson DT, Zhang Y, Anthony JM, Naimark A, Anderson JJ. Weight loss reduces the risk for symptomatic knee osteoarthritis in women. The Framingham Study. *Ann Intern Med.* 1992; 116: 535-539

Fibel KH, Hillstrom HJ, Halpern BC. State-of-the-Art management of knee osteoarthritis. *WJCC.* 2015; 3: 89-101

Fithian DC, Kelly MA, Mow VC. Material properties and structure-function relationships in the menisci. *Clin. Orthop. Relat. Res.* 1990; 252: 19-31

Fox AJS, Bedi A, Rodeo SA. The basic science of articular cartilage: structure, composition, and function. *JSHS.* 2009; 1: 461-468

Fox AJS, Bedi A, Rodeo SA. The basic science of human knee menisci: structure, composition, and function. *JSHS.* 2012; 4: 340-351

Frisbie DD, Kawcak CE, Trotter GW, Powers BE, Walton RM, McIlwraith CW. Effects of triamcinolone acetonide on an in vivo equine osteochondral fragment exercise model. *Equine Vet J.* 1997; 29: 349-359

Goldring MB, Marcu KB. Cartilage homeostasis in health and rheumatic diseases. *Arthritis Res Ther.* 2009; 11: 224

Guermazi A, Roemer FW, Haugen IK, Crema MD, Hayashi D. MRI-based semiquantitative scoring of joint pathology in osteoarthritis. *Nat Rev Rheumatol.* 2013; 9: 236-251

Gupte CM, Smith A, McDermott ID, Bull AM, Thomas RD, Amis AA. Meniscomfemoral ligaments revisited. Anatomical study, age correlation and clinical implications. *J Bone Joint Surg Br.* 2002; 84: 846-851

Habib G, Zahran R, Najjar R, Badarny S, Jabbour A, Artul S, Hakim G, Jabaly-Habib H. The effect of intra-articular injection of Diprosan at the knee joint on the hypothalamic-pituitary-adrenal axis. *Swiss Med Wkly.* 2015; 145: w14134

Han EH, Chen SS, Klisch SM, Sah RL. Contribution of proteoglycan osmotic swelling pressure to the compressive properties of articular cartilage. *Biophys J.* 2011; 101: 916-924

Hauser RA. The acceleration of articular cartilage degeneration in osteoarthritis by nonsteroidal anti-inflammatory drugs. *JOP*. 2010; 2: 305-322

Hellio Le Graverand MP, Vignon E, Otterness IG, Hart DA. Early changes in lapine menisci during osteoarthritis development: part I: cellular and matrix alterations. *Osteoarthr Cartilage*. 2001; 9: 56-64

Herwig J, Egner E, Buddecke E. Chemical changes of human knee joint menisci in various stages of degeneration. *Ann Rheum Dis*. 1984; 43: 635-640

Hontoir F, Clegg P, Nisolle JF, Tew S, Vandeweerdt JM. Magnetic resonance compositional imaging of articular cartilage: What can we expect in veterinary medicine? *Vet J*. 2015; 205: 11-20

Howell R, Kumar NS, Patel N, Tom J. Degenerative meniscus: Pathogenesis, diagnosis, and treatment options. *World J Orthop*. 2014; 5: 597-602

Huang K, Wu LD. Aggrecanase and aggrecan in osteoarthritis: a review. *Int J Med Res*. 2008; 36: 1149-1160

Ishikawa K. Effect of intra-articular corticosteroid on the meniscus. *J Bone Joint Surg Am*. 1981; 63: 120-130

Johnson VL, Hunter DJ. The epidemiology of osteoarthritis. *Best Pract. Res. Clin. Rheumatol*. 2014; 28: 5-15

Katsuragawa Y, Saitoh K, Tanaka N, Wake M, Ikeda Y, Furukawa H, Tohma S, Sawabe M, Ishiyama M, Yagishita S, Suzuki R, Mitomi H, Fukui N. Changes of human menisci in osteoarthritic knee joints. *Osteoarthr Cartilage*. 2010; 18: 1133-1143

Kilkenny C, Browne W, Cuthill IC, Emerson M, Altman DG. Animal research: Reporting in vivo experiments: The arrive guidelines. *Br J pharmacol*. 2010; 160: 1577-1579

Kraus VB, Stabler TV, Kong SY, Varju G, McDaniel G. Measurement of synovial fluid volume using urea. *Osteoarthr Cartilage*. 2007; 15: 1217-1220

Larking. Causation Review: meniscal tears. 2010 (Thesis)

Li ZC, Han N, Li X, Li G, Liu YZ, Sun GX, Wang Y, Chen GT, Li GF. Decreased expression of microRNA-130a correlates with TNF- α in the development of osteoarthritis. *Int J Clin Exp Pathol*. 2015; 8: 2555-2564

Little CB, Smith MM, Calkins MA, Read RA, Murphy MJ, Barry FP. The OARSI histopathology initiative - recommendations for histological assessments of osteoarthritis in sheep and goats. *Osteoarthr Cartilage*. 2010; 18: 80-92

Liu F, Samsonov A, Wilson JJ, Blankenbaker DG, Block WF, Kijowski R. Rapid in vivo multicomponent T2 mapping of human knee menisci. *J Magn Reson Imaging*. 2015; 42: 1321-1328

- Liu N, Wang W, Zhao Z, Zhang T, Song Y. Autophagy in human articular chondrocytes is cytoprotective following glucocorticoid stimulation. *Mol Med Rep.* 2014; 9: 2166-2172
- Lodish H, Berk A, Zipursky SL, Matsudaira P, Baltimore D. *Molecular cell Biology* (4th edition).
- Loeser RF, Goldring SR, Scanzello CR, Goldring MB. Osteoarthritis: a disease of the joint as an organ. *Arthritis Rheum.* 2012; 64: 1697-1707
- Loeser RF. Age-related changes in the musculoskeletal system and the development of osteoarthritis. *Clin Geriatr Med.* 2010; 26: 371-386
- Loeser RF. Molecular mechanisms of cartilage destruction: mechanics, inflammatory mediators, and aging collide. *Arthritis Rheum.* 2006; 54: 1357-1360
- Lu X, Mow V. Biomechanics of articular cartilage and determination of material properties. *Med Sci Sports Exerc.* 2008; 40: 193-199
- Lu YC, Evans CH, Grodzinsky AJ. Effects of short-term glucocorticoid treatment on changes in cartilage matrix degradation and chondrocyte gene expression induced by mechanical injury and inflammatory cytokines. *Arthritis Res Ther.* 2011; 13: R142
- Makris EA, Hadidi P, Athanasiou KA. The knee meniscus: structure-function, pathophysiology, current repair techniques, and prospects for regeneration. *Biomaterials.* 2011; 32: 7411-7431
- Martel-Pelletier J, Boileau C, Pelletier JP, Roughley PJ. Cartilage in normal and osteoarthritis conditions. *Best Pract Res Cl Rh.* 2008; 22: 351-384
- Masouros SD, McDermott ID, Amis AA, Bull AM. Biomechanics of the meniscus-meniscal ligament construct of the knee. *Knee Surg Sports Traumatol Arthrosc.* 2008; 16: 1121-1132
- Matthews JJ, Williams K, Mahendra G, Mahoney D, Swales C, Sabokar A, Price A, Athanasou NA, Gibbons CLMH. Synovial fluid and membrane cytology in inflammatory osteoarthritis of the knee – a predictor for unicompartmental or total knee arthroplasty. *J Bone Joint Surg.* 2010; 92: 412
- McAlindon TE, Bannuru RR, Sullivan MC, Arden NK, Berenbaum F, Bierma-Zeinstra SM, Hawker GA, Henrotin Y, Hunter DJ, Kawaguchi H, Kwoh K, Lohmander S, Rannou F, Roos EM, Underwood M. OARSI guidelines for the non-surgical management of knee osteoarthritis. *Osteoarthr Cartilage.* 2014; 22: 363-388
- McDevitt CA, Webber RJ. The ultrastructure and biochemistry of meniscal cartilage. *Clin Orthop Relat Res.* 1990; 252: 8-18
- McIlwraith CW. The use of intra-articular corticosteroids in the horse: what is known on a scientific basis. *Equine Vet J.* 2010; 42: 563-571

- Melrose J, Smith S, Cake M, Read R, Whitelock J. Comparative spatial and temporal localisation of perlecan, aggrecan and type I, II and IV collagen in the ovine meniscus: an ageing study. *Histochem Cell Biol.* 2005; 124: 225-235
- Mezhov V, Teichtahl AJ, Strasser R, Wluka AE, Cicuttini FM. Meniscal pathology - the evidence for treatment. *Arthritis Research & Therapy.* 2014; 16: 206
- Miller RR, McDevitt CA. Thrombospondin in ligament, meniscus and intervertebral disc. *Biochim Biophys Acta.* 1991; 1115: 85-88
- Murphy L, Schwartz TA, Helmick CG, Renner JB, Tudor G, Koch G, Dragomir A, Kalsbeek WD, Luta G, Jordan JM. Lifetime risk of symptomatic knee osteoarthritis. *Arthritis Rheum.* 2008; 59: 1207-1213
- Nakagawa Y, Muneta T, Kondo S, Mizuno M, Takakuda K, Ichinose S, Tabuchi T, Koga H, Tsuji K, Sekiya I. Synovial mesenchymal stem cells promote healing after meniscal repair in microminipigs. *Osteoarthr Cartilage.* 2015; 23: 1007-1017
- Nakazawa F, Matsuno H, Yudoh K, Watanabe Y, Katayama R, Kimura T. Corticosteroid treatment induces chondrocyte apoptosis in an experimental arthritis model and in chondrocyte cultures. *Clin Exp Rheumatol.* 2002; 20: 773-781
- Noble J, Hamblen DL. The pathology of the degenerate meniscus lesion. *J Bone Joint Surg Br.* 1975; 57: 180-186
- Notoya K, Jovanovic DV, Reboul P, Martel-Pelletier J, Mineau F, Pelletier JP. The induction of cell death in human osteoarthritis chondrocytes by nitric oxide is related to the production of prostaglandin E2 via the induction of cyclooxygenase-2. *J Immunol.* 2000; 165: 3402-3410
- Pauli C, Grogan SP, Patil S, Otsuki S, Hasegawa A, Koziol J, Lotz MK, D'Lima DD. Macroscopic and histopathologic analysis of human knee menisci in aging and osteoarthritis. *Osteoarthr Cartilage.* 2011; 19: 1132-1141
- Pearle AD, Warren RF, Rodeo SA. Basic science of articular cartilage and osteoarthritis. *Clin Sports Med.* 2005; 24: 1-12
- Pelletier JP, Martel-Pelletier J. Protective effects of corticosteroids on cartilage lesions and osteophyte formation in the Pond-Nuki dog model of osteoarthritis. *Arthritis Rheum.* 1989; 32: 181-193
- Petersen W, Tillmann B. Collagenous fibril texture of the human knee joint menisci. *Anat Embryol (Berl).* 1998; 197: 317-324
- Piccione G, Foà A, Bertolucci C, Caola G. Daily rhythm of salivary and serum urea concentration in sheep. *J Circadian Rhythms.* 2006; 4-16
- Poole AR. Osteoarthritis as a Whole Joint Disease. *HSSJ.* 2012; 8: 4-6

Poole CA, Matsuoka A, Schofield JR. Chondrons from articular cartilage. III. Morphologic changes in the cellular microenvironment of chondrons isolated from osteoarthritic cartilage. *Arthritis Rheum.* 1991; 34: 22-35

Rathod JA, Patel DI, Jasoliya V. Pre and Post Treatment Comparative Study of Meniscus Tears Treated with Intraarticular Steroid Injection. *Natl J Community Med.* 2014; 5: 245-248

Rokkanen P, Paatsama S, Rissanen P. The influence of certain hormones on the meniscus of the femoro-tibial (stifle) joint. A histological and histo-quantitative study on young dogs. *J Small Anim Pract.* 1967; 8: 221-227

Roos H, Adalberth T, Dahlberg L, Lohmander LS. Osteoarthritis of the knee after injury to the anterior cruciate ligament or meniscus: the influence of time and age. *Osteoarthr Cartilage.* 1995; 3: 261-267

Ross A, Hauser MD. The deterioration of articular cartilage in osteoarthritis by corticosteroid injections. *JOP.* 2009; 1: 107-123

Sanchez-Adams J, Willard VP, Athanasiou KA. Regional variation in the mechanical role of knee meniscus glycosaminoglycans. *J Appl Physiol.* 2011; 111: 1590-1596

Scott PG, Nakano T, Dodd CM. Isolation and characterization of small proteoglycans from different zones of the porcine knee meniscus. *Biochim Biophys Acta.* 1997; 1336: 254-262

Shafford HL, Hellyer PW, Turner AS. Intra-articular lidocaine plus bupivacaine in sheep undergoing stifle arthrotomy. *Vet Anaesth Analg.* 2004; 31: 20-26

Sharif M, Whitehouse A, Sharman P, Perry M, Adams M. Increased apoptosis in human osteoarthritic cartilage corresponds to reduced cell density and expression of caspase-3. *Arthritis Rheum.* 2004; 50: 507-515

Sharma AR, Jagga S, Lee SS, Nam JS. Interplay between cartilage and subchondral bone contributing to pathogenesis of osteoarthritis. *Int J Mol Sci.* 2013; 14: 19805-19830

Sharma L, Eckstein F, Song J, et al. Relationship of meniscal damage, meniscal extrusion, malalignment, and joint laxity to subsequent cartilage loss in osteoarthritic knees. *Arthritis Rheum.* 2008; 58: 1716-1726

Son M, Goodman SB, Chen W, Hargreaves BA, Gold GE, Levenston ME. Regional variation in T1ρ and T2 times in osteoarthritic human menisci: correlation with mechanical properties and matrix composition. *Osteoarthr Cartilage.* 2013; 21: 796-805

Sridharan G, Shankar AA. Toluidine blue: A review of its chemistry and clinical utility. *J Oral Maxillofac Pathol.* 2012; 16: 251-255

Studer RK, Bergman R, Stubbs T, Decker K. Chondrocyte response to growth factors is modulated by p38 mitogen-activated protein kinase inhibition. *Arthritis Res Ther.* 2004; 6: 56-64

- Sun Y, Mauerhan DR, Kneisl JS, Norton HJ, Zinchenko N, Ingram J, Hanley EN Jr, Gruber HE. Histological examination of collagen and proteoglycan changes in osteoarthritic menisci. *Open Rheumatol J*. 2012; 6: 24-32
- Takebe K, Nishiyama T, Hayashi S, Hashimoto S, Fujishiro T, Kanzaki N, Kawakita K, Iwasa K, Kuroda R, Kurosaka M. Regulation of p38 MAPK phosphorylation inhibits chondrocyte apoptosis in response to heat stress or mechanical stress. *Int J Mol Med*. 2011; 27: 329-335
- Taylor WR, Poepplau BM, König C, Ehrig RM, Zachow S, Duda GN, Heller MO. The medial-lateral force distribution in the ovine stifle joint during walking. *J Orthop Res*. 2011; 29: 567-571
- Tehranzadeh J, Booya F, Root J. Cartilage metabolism in osteoarthritis and the influence of viscosupplementation and steroid: a review. *Acta Radiol*. 2005; 46: 288-296
- Van der Bracht H, Verdonk R, Verbruggen G, Elewaut D, Verdonk P. Cell-based meniscus tissue engineering; *Topics in Tissue Engineering*. 2007; 3: 1-12.
- Vandeweerdt JM, Kirschvink N, Muylkens B, Depiereux E, Clegg P, Herteman N, Lamberts M, Bonnet P, Nisolle JF. A study of the anatomy and injection techniques of the ovine stifle by positive contrast arthrography, computed tomography arthrography and gross anatomical dissection. *Vet J*. 2012; 193: 426-432
- Vandeweerdt JM, Zhao Y, Nisolle JF, Zhang W, Zhihong L, Clegg P, Gustin P. Effect of corticosteroids on articular cartilage: have animal studies said everything? *Fundam Clin Pharmacol*. 2015; 29: 427-438
- Verdonk PC, Demurie A, Almqvist KF, Veys EM, Verbruggen G, Verdonk R. Transplantation of viable meniscal allograft. Survivorship analysis and clinical outcome of one hundred cases. *J Bone Joint Surg Am*. 2005; 87: 715-724
- Vonk LA, Kroeze RJ, Doulabi BZ, Hoogendoorn RJ, Huang C, Helder MN, Everts V, Bank RA. Caprine articular, meniscus and intervertebral disc cartilage: an integral analysis of collagen network and chondrocytes. *Matrix Biol*. 2010; 29: 209-218
- Watrín-Pinzano A, Ruaud JP, Cheli Y, Gonord P, Grossin L, Bettembourg-Brault I, Gillet P, Payan E, Guillot G, Netter P, Loeuille D. Evaluation of cartilage repair tissue after biomaterial implantation in rat patella by using T2 mapping. *MAGMA*. 2004; 17: 219-228
- Wernecke C, Braun HJ, Drago J. The effect of intra-articular corticosteroid on articular cartilage. *OJSM*. 2015; 3: 1-7
- Wilusz RE, Sanchez-Adams J, Guilak F. The structure and function of the pericellular matrix of articular cartilage. *Matrix Biol*. 2014; 39: 25-32
- Zarins ZA, Bolbos RI, Pialat JB, Link TM, Li X, Souza RB, Majumdar S. Cartilage and meniscus assessment using T1rho and T2 measurements in healthy subjects and patients with osteoarthritis. *Osteoarthr Cartilage*. 2010; 18: 1408-1416

Zhang X, Aoyama T, Ito A, Tajino J, Nagai M, Yamaguchi S, Iijima H, Kuroki H. Regional comparisons of porcine menisci. *J Orthop Res.* 2014; 32: 1602-1611

Zhao J, Huang S, Zheng J, Zhong C, Tang C, Zheng L, Zhang Z, Xu J. Changes of rabbit meniscus influenced by hyaline cartilage injury of osteoarthritis. *Int J Clin Exp Med.* 2014; 7: 2948-2956